

# The American Journal of Sports Medicine

<http://ajs.sagepub.com/>

---

## **Anterior Talofibular Ligament Ruptures, Part 2: Biomechanical Comparison of Anterior Talofibular Ligament Reconstruction Using Semitendinosus Allografts With the Intact Ligament**

Thomas O. Clanton, Nicholas A. Viens, Kevin J. Campbell, Robert F. LaPrade and Coen A. Wijdicks

*Am J Sports Med* 2014 42: 412 originally published online November 26, 2013

DOI: 10.1177/0363546513509963

The online version of this article can be found at:

<http://ajs.sagepub.com/content/42/2/412>

---

Published by:



<http://www.sagepublications.com>

On behalf of:



American Orthopaedic Society for Sports Medicine

**Additional services and information for *The American Journal of Sports Medicine* can be found at:**

**Email Alerts:** <http://ajs.sagepub.com/cgi/alerts>

**Subscriptions:** <http://ajs.sagepub.com/subscriptions>

**Reprints:** <http://www.sagepub.com/journalsReprints.nav>

**Permissions:** <http://www.sagepub.com/journalsPermissions.nav>

>> [Version of Record](#) - Jan 31, 2014

[OnlineFirst Version of Record](#) - Nov 26, 2013

[What is This?](#)

# Anterior Talofibular Ligament Ruptures, Part 2

## Biomechanical Comparison of Anterior Talofibular Ligament Reconstruction Using Semitendinosus Allografts With the Intact Ligament

Thomas O. Clanton,<sup>\*†‡</sup> MD, Nicholas A. Viens,<sup>†‡</sup> MD, Kevin J. Campbell,<sup>†</sup> BS, Robert F. LaPrade,<sup>†‡</sup> MD, PhD, and Coen A. Wijdicks,<sup>†</sup> PhD  
*Investigation performed at the Department of BioMedical Engineering, Steadman Philippon Research Institute, Vail, Colorado*

**Background:** Anatomic reconstructions of the lateral ankle ligaments with grafts have been proposed for patients with generalized ligamentous laxity, long-standing instability with attenuated native tissues, varus hindfoot misalignment, or failed prior lateral ligament surgery and for very large patients or elite athletes because of increased demands.

**Hypothesis:** Anatomic reconstruction of the anterior talofibular ligament (ATFL) using a semitendinosus allograft fixed with bio-composite interference fit screws would have similar biomechanical properties to the intact ATFL at time zero in a cadaveric model.

**Study Design:** Controlled laboratory study.

**Methods:** Allograft reconstruction of the ATFL was performed in 6 fresh-frozen cadaveric ankles. The specimens were loaded to failure to determine the strength and stiffness of the reconstruction and compared with data from 6 cadaveric specimens with intact ATFLs.

**Results:** The mean ultimate load to failure of the allograft reconstruction ( $170.7 \pm 54.8$  N) was not significantly different from that of the intact ATFL ( $154.0 \pm 63.7$  N). The mean stiffness of the allograft reconstruction ( $23.1 \pm 9.3$  N/mm) was also not significantly different from that of the intact ATFL ( $14.5 \pm 4.4$  N/mm).

**Conclusion:** Anatomic reconstruction of the ATFL with allografts demonstrated similar strength and stiffness to the native ligament at time zero in a fresh-frozen cadaveric model.

**Clinical Relevance:** This technique of anatomic reconstruction of the ATFL with allografts has biomechanical validation for use in clinical situations where a Broström repair of the lateral ankle ligaments is unlikely to be successful or has previously failed.

**Keywords:** allograft reconstruction; anterior talofibular ligament (ATFL); Broström failure; interference fit screws; lateral ankle ligament rupture; semitendinosus graft

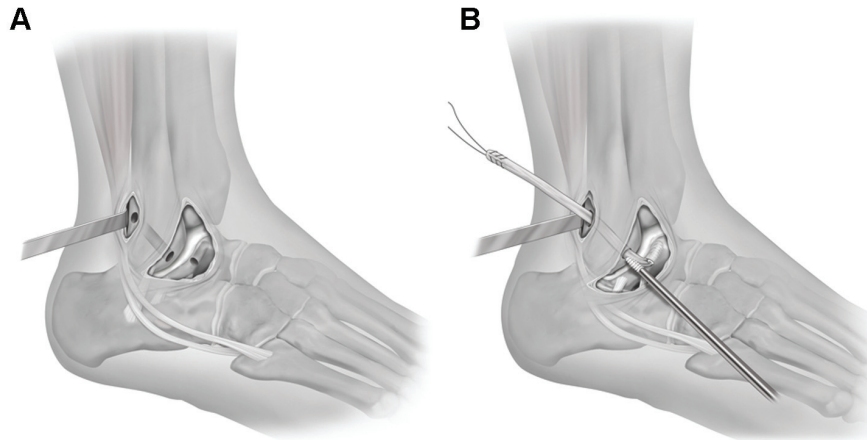
\*Address correspondence to Thomas O. Clanton, MD, Steadman Philippon Research Institute, 181 West Meadow Drive, Suite 1000, Vail, CO 81657 (e-mail: tclanton@thesteadmanclinic.com).

<sup>†</sup>Steadman Philippon Research Institute, Vail, Colorado.

<sup>‡</sup>The Steadman Clinic, Vail, Colorado.

One or more of the authors has declared the following potential conflict of interest or source of funding: Dr Clanton and Dr LaPrade consult for Arthrex Inc. Arthrex provided cadaveric specimens and surgical equipment for this study.

Anatomic repair of the lateral ankle ligaments as described by Broström,<sup>5</sup> often augmented by the Gould modification,<sup>21</sup> remains the standard surgical option for treating patients with chronic lateral ankle instability.<sup>2,3,14,32</sup> Clinical outcomes utilizing this technique for certain patient groups have been reported to be less successful.<sup>39</sup> Specifically, patients with generalized ligamentous laxity, long-standing ankle instability, or failed prior lateral ligament surgery are less likely to have adequate local tissue for imbrication techniques alone and have experienced inferior clinical results.<sup>29,30</sup> For these patient subsets, as well as very large patients, elite athletes, or patients with varus



**Figure 1.** Right ankle specimens. (A) Tunnels are placed in the anterolateral fibula at the origin of the anterior talofibular ligament (ATFL) and along the lateral articular margin of the talus at the insertion site of the ATFL. Note the placement of the right-angle retractor through a second proximal incision posterior to the fibula that was used to protect the peroneal tendons during tunnel placement and graft tensioning. (B) Reconstruction of the ATFL with a single-bundle semitendinosus allograft secured with 2 biocomposite interference fit screws at the ligament origin on the fibula and insertion site on the talus.

hindfoot misalignment, who are all likely to place added demands on the repaired lateral ligament and therefore have increased risks of failure,<sup>9,19,40</sup> various anatomic reconstructions with autografts and allografts have been reported with promising, but often limited, early results.<sup>8</sup> To our knowledge, biomechanical evaluations of graft reconstruction of the lateral ankle ligament using modern fixation techniques are currently unavailable.

The purpose of this study was to describe a technique of anatomic reconstruction of the anterior talofibular ligament (ATFL) using a semitendinosus allograft and perform a biomechanical comparison with the intact ATFL in a fresh-frozen cadaveric model. We hypothesized that anatomic reconstruction of the ATFL would exhibit similar biomechanical properties at time zero when compared with the isolated intact ATFL.

## MATERIALS AND METHODS

### Specimens

Six fresh-frozen cadaveric ankles were thawed, dissected, and utilized specifically for part 2 of this 2-part study. Specimens were included if they had no prior ankle ligament tears or surgery, were age  $\leq 65$  years (mean, 54.8 years; range, 45-64 years), and had no history of cancer as the cause of death. Before the initiation of this 2-part study, 24 specimens were randomized to 1 of 4 groups for testing and analysis. Two experimental groups are discussed here: (1) intact ATFL and (2) allograft reconstruction. Data from the other 2 groups were presented in part 1. The 6 intact ATFL specimens were used for both part 1 and part 2 of this study. Specimens were kept moist with saline to prevent tissue desiccation through testing.

### Dissection Procedure

For all ankle specimens, a curvilinear incision was made anterior to the fibula, allowing identification and sectioning of the ATFL. Each specimen was then assessed clinically with the anterior drawer test to confirm that complete sectioning of the ATFL had been performed.

### Allograft Reconstruction Technique

Reconstruction of the ATFL was performed using human semitendinosus allografts (AlloSource, Centennial, Colorado) in 6 ankle specimens. The hamstring grafts, approximately 4.5 mm in diameter and at least 150 mm in length, were kept moist and tensioned at 89 N for 15 minutes before implantation to reduce graft creep.<sup>23</sup> Once the distal fibula and lateral talus were identified, the sectioned ends of the ATFL and guidelines from prior anatomic literature<sup>6,20,34,44</sup> were used to establish the specific landmarks for anatomic reconstruction of the ATFL. A 5.0-mm tunnel was reamed to a depth of 25 mm over an islet pin (Arthrex Inc, Naples, Florida) that was placed at the insertion of the ATFL just off the articular margin of the lateral talus and aimed approximately 20° toward the talar body. A second 5.0-mm tunnel was overreamed at the superior aspect of the ATFL origin on the distal fibula from the anterior distal fibula through to the posterior fibula more proximally, re-creating the 25° angle of the native ATFL from the horizontal plane (Figure 1A).<sup>44</sup> Consistency with manufacturer and reamer type was emphasized during the surgical protocol to minimize aperture variability and tunnel dimensions.<sup>18</sup> A 5.5-mm biocomposite interference fit screw (BioComposite Tenodesis Screw, Arthrex Inc) was loaded with the semitendinosus allograft and seated into the talar tunnel. With the graft secured in the talus, the opposite end of the graft was passed proximally through

<sup>8</sup>References 4, 6, 7, 12, 13, 15, 24, 25, 27, 28, 31, 33, 35, 42, 43, 46.

TABLE 1  
Specimen Demographics

Group	Demographics	
	Male:Female, n	Age, Mean (Range), y
Intact anterior talofibular ligament	4:2	55.6 (45-64)
Allograft reconstruction	5:1	54.0 (46-58)

the fibular tunnel. The foot was then held in relaxed plantar flexion (ie, 10°-20°) with 5° of eversion with a bump placed under the tibia, allowing the foot to reduce under the ankle mortise and avoid any anterior translation.<sup>41</sup> A second 5.5-mm interference fit screw was then seated into the fibular tunnel while holding the graft under maximum manual tension (Figure 1B). The anterior drawer test was manually applied to each specimen to verify the restoration of ankle stability.

### Specimen Preparation and Biomechanical Testing

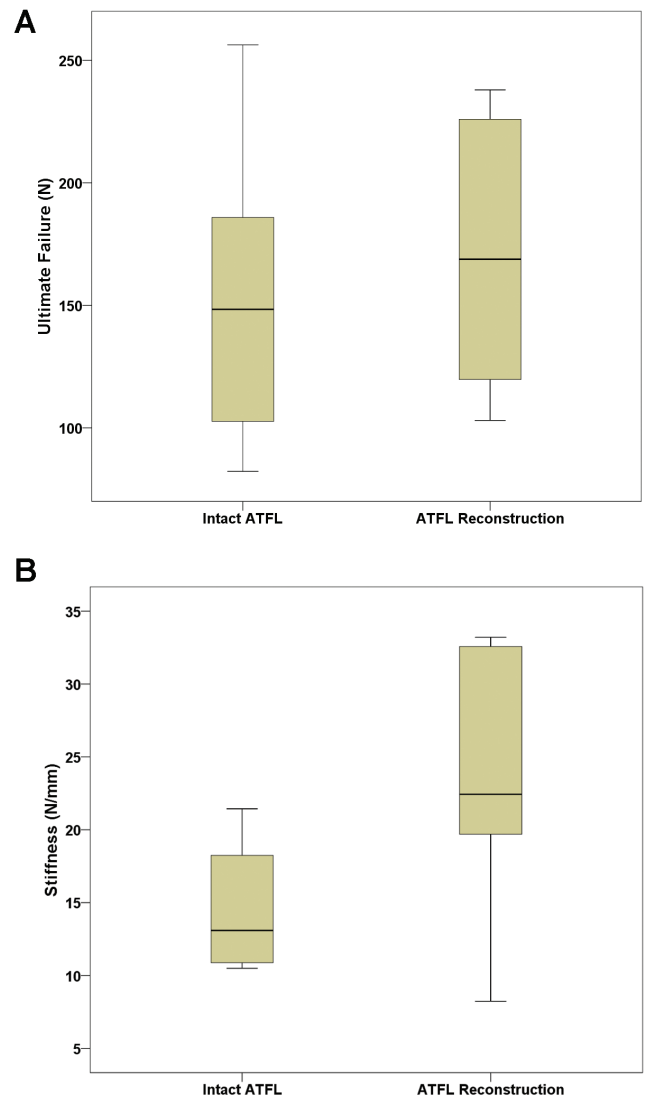
Biomechanical testing methodology has been previously published,<sup>45</sup> with modifications described in detail in part 1. After each specimen was secured in a custom fixture, the construct was mounted to the test frame actuator of a tensile testing machine with the foot in 20° of inversion and 10° of plantar flexion (Instron E10000 ElectroPuls Dynamic Testing System, Instron Systems, Norwood, Massachusetts). A video extensometer was used to measure the displacement of the fibula relative to the talus as it was pulled at 20 mm/min by the actuator (Advanced Video Extensometer, Instron Systems). The data were recorded with Instron BlueHill 2 software (Instron Systems), and further analysis and calculations were performed with Microsoft Excel software (Microsoft Inc, Seattle, Washington).

### Statistical Analysis

Statistical analysis was performed with predictive analytics software (SPSS version 20, SPSS Inc, Chicago, Illinois). The study compared data for each group using a 1-way analysis of variance (ANOVA). For ANOVAs that demonstrated a statistically significant difference, a post hoc Tukey honestly significant difference test was conducted to assess the location of the means that were statistically significant between the groups. A significant difference was determined to be present for  $P < .05$ .

## RESULTS

No significant differences were seen for demographic variables between the study groups (Table 1). The mean ultimate load to failure of the allograft reconstruction ( $170.7 \pm 54.8$  N) was not significantly different than that of the intact ATFL ( $154.0 \pm 63.7$  N). The mean stiffness of the allograft reconstruction ( $23.1 \pm 9.3$  N/mm) was also not significantly different than that of the intact ATFL ( $14.5 \pm 4.4$  N/mm) (Figure 2). Reconstruction of



**Figure 2.** Box plots comparing biomechanical data between the intact anterior talofibular ligament (ATFL) and allograft reconstruction of the ATFL. The horizontal line within the box indicates the median. Each box extends from the 25th to 75th percentile. The vertical bars represent the smallest and largest observed values. (A) Ultimate load to failure in Newtons (N). (B) Stiffness in Newtons per millimeter (N/mm).

the ATFL failed because of graft pullout from the fibular tunnel ( $n = 5/6$ ) and the talar tunnel (1/6).

## DISCUSSION

Anatomic reconstruction of the ATFL using a semitendinosus allograft fixed with biocomposite interference fit screws demonstrated similar strength and stiffness to the intact ATFL. This study represents the first biomechanical evaluation of anatomic reconstruction of the ATFL using a free tendon graft compared with the native ligament. In

comparison with prior research, this study demonstrates that allograft reconstruction of the ATFL also produces superior immediate strength and stiffness when compared with the standard Broström repair of the ATFL.<sup>45</sup> This study provides biomechanical validation for the described technique of anatomic reconstruction of the ATFL using a semitendinosus allograft because it closely reapproximated the strength and stiffness properties of the native ligament. Because of the use of a routinely available allograft and interference fit screws, this anatomic reconstruction of the lateral ligament not only allows for reproducible and secure fixation but also independent placement and tensioning of both the ATFL and calcaneofibular ligament (CFL) (if required) grafts.<sup>33</sup> This technique also provides a valid option that does not require the use of a patient's normal tendon, such as the peroneus brevis,<sup>19</sup> in clinical situations where a standard Broström repair has previously failed or is likely to be insufficient.

Prisk et al<sup>36</sup> evaluated ankle contact mechanics and motion in a cadaveric model using a 6 degrees of freedom robotic system and demonstrated that tendon graft reconstruction more closely reapproximated native contact mechanics under inversion loads than did either the Broström or Broström-Gould repairs. Despite the improvements, all 3 techniques were unable to completely restore normal ankle mechanics.<sup>36</sup> Information about the relative strength and stiffness of a modern graft reconstruction compared with the isolated intact ATFL has remained unknown before the current study.

Several methods of graft reconstruction of the lateral ankle ligaments have previously been reported with good clinical success at short-term follow-up.<sup>11</sup> Specific technical complexities, added operative time, and potential surgeon unfamiliarity with graft harvest, as well as patient morbidity involved with the use of autografts, could all limit the utility of some of these techniques in practice. For instance, despite good and excellent clinical results and restored ankle stability in all 28 patients (29 ankles) at a mean follow-up of 23 months, the ATFL and CFL reconstruction technique popularized by Coughlin et al<sup>12,13</sup> utilizes potentially difficult and time-consuming steps of tunnel creation, gracilis tendon autograft harvest, and graft fixation reliant upon tendon-to-tendon and tendon-to-periosteum sutures.

While the debate concerning the merits of autograft versus allograft tissue remains largely unresolved, as exhibited by anterior cruciate ligament reconstruction in the knee,<sup>8,17,22,37</sup> less controversy seems to surround the relative advantages of using modern implants for graft fixation. Biocomposite interference fit screws provide adequate tendon-to-bone strength in the foot and ankle with the added benefits of ease and speed of use and the need for less tendon length than traditional methods of tendon-to-tendon suture fixation.<sup>10,11,38</sup> Biocomposite interference fit screw constructs, as tested by both Sabonghy et al<sup>38</sup> and Jeys et al,<sup>26</sup> may withstand greater loads than the previously reported strength of the native ATFL.<sup>1</sup> Finally, the low rates of short-term complications

reported using bioabsorbable screws in the foot and ankle<sup>10</sup> add further support for their use in reconstruction of the lateral ankle ligaments, as in our preferred surgical technique described and investigated here.

Limitations to this study include the increased age of the specimens compared with the typically younger, athletic population in whom reconstructions of the lateral ankle ligament are performed.<sup>16,46</sup> In addition, the bone density of the specimens was not evaluated during this study and, therefore, was not controlled for during data analysis. Nevertheless, the random assignment of each specimen to 1 of 4 experimental groups before initiating this 2-part study was performed to minimize the potential confounding effects of age and tissue quality on the results. Given the similar age distributions between the groups, we believe that the effect of specimen age when comparing groups was limited. This study demonstrates the biomechanical properties of allograft reconstruction of the ATFL at time zero only, which eliminates the effects of biological healing over time. Finally, given that this study evaluated allograft reconstruction of the ATFL alone and did not incorporate reconstruction of the CFL, future studies that can accurately account for the contributions of both components of reconstruction of the lateral ligaments will be valuable to pursue.

## CONCLUSION

Anatomic reconstruction of the ATFL using an allograft semitendinosus tendon secured with biocomposite interference fit screws demonstrated similar strength and stiffness to the native ligament at time zero in a fresh-frozen cadaveric model. This study provides biomechanical validation supporting the use of a reproducible technique of anatomic reconstruction of the ATFL. This can be used in patients who have failed prior repairs of the lateral ankle ligaments or those with specific clinical factors predisposing them to Broström repair failure, including generalized ligamentous laxity, long-standing ankle instability with attenuated native tissues, varus hindfoot misalignment, and increased demands such as large patient size or participation in elite athletics.

## ACKNOWLEDGMENT

The authors acknowledge Kyle S. Jansson for his mechanical expertise in developing the testing fixture for this study.

## REFERENCES

1. Attarian DE, McCrackin HJ, Devito DP, McElhaney JH, Garrett WE Jr. A biomechanical study of human lateral ankle ligaments and autogenous reconstructive grafts. *Am J Sports Med.* 1985;13:377-381.
2. Baumhauer JF, O'Brien T. Surgical considerations in the treatment of ankle instability. *J Athl Train.* 2002;37:458-462.
3. Bell SJ, Mologne TS, Sittler DF, Cox JS. Twenty-six year results after Broström procedure for chronic lateral ankle instability. *Am J Sports Med.* 2006;34:975-978.
4. Boyer DS, Younger ASE. Anatomic reconstruction of the lateral ligament complex of the ankle using a gracilis autograft. *Foot Ankle Clin N Am.* 2006;11:585-595.

<sup>11</sup>References 7, 13, 15, 24, 25, 28, 31, 33, 35, 42, 43, 46.

5. Broström L. Sprained ankles, VI: surgical treatment of "chronic" ligament ruptures. *Acta Chir Scand*. 1966;132:551-565.
6. Burks RT, Morgan J. Anatomy of the lateral ankle ligaments. *Am J Sports Med*. 1994;22:72-77.
7. Caprio A, Oliva F, Treia F, Maffulli N. Reconstruction of the lateral ankle ligaments with allograft in patients with chronic ankle instability. *Foot Ankle Clin N Am*. 2006;11:597-605.
8. Carey JL, Dunn WR, Dahm DL, Zeger SL, Spindler KP. A systematic review of anterior cruciate ligament reconstruction with autograft compared with allograft. *J Bone Joint Surg Am*. 2009;91:2242-2250.
9. Chilvers M, Manoli A II. The subtle cavus foot and association with ankle instability and lateral foot overload. *Foot Ankle Clin N Am*. 2008;13:315-322.
10. Clanton TO, Betech AA, Bott AM, et al. Complications after tendon transfers in the foot and ankle using bioabsorbable screws. *Foot Ankle Int*. 2013;34:486-490.
11. Clanton TO, Perlman M. Interference screw fixation of tendon transfers in the foot and ankle. *Foot Ankle Int*. 2002;23:355-356.
12. Coughlin MJ, Matt V, Schenck RC Jr. Augmented lateral ankle reconstruction using a free gracilis graft. *Orthopedics*. 2002;25:31-35.
13. Coughlin MJ, Schenck RC Jr, Grebing BR, Treme G. Comprehensive reconstruction of the lateral ankle for chronic instability using a free gracilis graft. *Foot Ankle Int*. 2004;25:231-241.
14. DiGiovanni CW, Brodsky A. Current concepts: lateral ankle instability. *Foot Ankle Int*. 2006;27:854-866.
15. Ellis SJ, Williams BR, Pavlov H, Deland J. Results of anatomic lateral ankle ligament reconstruction with tendon allograft. *HSS J*. 2011;7:134-140.
16. Ferran NA, Maffulli N. Epidemiology of sprains of the lateral ankle ligament complex. *Foot Ankle Clin N Am*. 2006;11:659-662.
17. Foster TE, Wolfe BL, Ryan S, Silvestri L, Kaye EK. Does the graft source really matter in the outcome of patients undergoing anterior cruciate ligament reconstruction? An evaluation of autograft versus allograft reconstruction results: a systematic review. *Am J Sports Med*. 2010;38:189-199.
18. Geeslin AG, Jansson KS, Wijdicks CA, Chapman MA, Fok AS, LaPrade RF. Tibial tunnel aperture irregularity after drilling with 5 reamer designs: a qualitative micro-computed tomography analysis. *Am J Sports Med*. 2011;39:825-831.
19. Girard P, Anderson RB, Davis WH, Isear JA Jr, Kiezbak GM. Clinical evaluation of the modified Broström-Evans procedure to restore ankle stability. *Foot Ankle Int*. 1999;20:246-252.
20. Golanó P, Vega J, de Leeuw PAJ, et al. Anatomy of the ankle ligaments: a pictorial essay. *Knee Surg Sports Traumatol Arthrosc*. 2010;18:557-569.
21. Gould N, Seligson D, Gassman J. Early and late repair of lateral ligament of the ankle. *Foot Ankle*. 1980;1:84-89.
22. Hinsenkamp M, Muylle L, Eastlund T, Fehily D, Noel L, Strong DM. Adverse reactions and events related to musculoskeletal allografts: reviewed by the World Health Organisation Project NOTIFY. *Int Orthop*. 2012;36:633-641.
23. Howard ME, Cawley PW, Losse GM, Johnston RB 3rd. Bone-patellar tendon-bone grafts for anterior cruciate ligament reconstruction: the effects of graft pretensioning. *Arthroscopy*. 1996;12:287-292.
24. Hua Y, Chen S, Jin Y, Zhang B, Li Y, Li H. Anatomic reconstruction of the lateral ligaments of the ankle with semitendinosus allograft. *Int Orthop*. 2012;36:2027-2031.
25. Ibrahim SA, Hamido F, Al Misfer AK, et al. Anatomical reconstruction of the lateral ligaments using gracilis tendon in chronic ankle instability: a new technique. *Foot Ankle Surg*. 2011;17:239-246.
26. Jeys L, Korrosis S, Stewart T, Harris NJ. Bone anchors or interference screws? A biomechanical evaluation for autograft ankle stabilization. *Am J Sports Med*. 2004;32:1651-1659.
27. Jeys LM, Harris NJ. Ankle stabilization with hamstring autograft: a new technique using interference screws. *Foot Ankle Int*. 2003;24:677-679.
28. Jung HG, Kim TH, Park JY, Bae EJ. Anatomic reconstruction of the anterior talofibular and calcaneofibular ligaments using a semitendinosus tendon allograft and interference screws. *Knee Surg Sports Traumatol Arthrosc*. 2012;20:1432-1437.
29. Karlsson J, Bergsten T, Lansinger O, Peterson L. Reconstruction of the lateral ligaments of the ankle for chronic lateral instability. *J Bone Joint Surg Am*. 1988;70:581-588.
30. Karlsson J, Bergsten T, Lansinger O, Peterson L. Surgical treatment of chronic lateral instability of the ankle joint: a new procedure. *Am J Sports Med*. 1989;17:268-274.
31. Kennedy JG, Smyth NA, Fansa AM, Murawski CD. Anatomic lateral ligament reconstruction in the ankle: a hybrid technique in the athletic population. *Am J Sports Med*. 2012;40:2309-2317.
32. Maffulli N, Ferran NA. Management of acute and chronic ankle instability. *J Am Acad Orthop Surg*. 2008;16:608-615.
33. McGarvey WC, Clanton TO. Lateral ankle ligament reconstruction using allograft and interference screw fixation. In: Wiesel SW, Easley ME, eds. *Operative Techniques in Foot and Ankle Surgery*. Philadelphia: Lippincott Williams & Wilkins; 2011:851-859.
34. Neuschwander TB, Indresano AA, Hughes TH, Smith BW. Footprint of the lateral ligament complex of the ankle. *Foot Ankle Int*. 2013;34:582-586.
35. Paterson R, Cohen B, Taylor D, Bourne A, Black J. Reconstruction of the lateral ligaments of the ankle using semi-tendinosus graft. *Foot Ankle Int*. 2000;21:413-419.
36. Prisk VR, Imhauser CW, O'Loughlin PF, Kennedy JG. Lateral ligament repair and reconstruction restore neither contact mechanics of the ankle joint nor motion patterns of the hindfoot. *J Bone Joint Surg Am*. 2010;92:2375-2386.
37. Prodromos CC, Fu FH, Howell SM, Johnson DH, Lawhorn K. Controversies in soft-tissue anterior cruciate ligament reconstruction: grafts, bundles, tunnels, fixation, and harvest. *J Am Acad Orthop Surg*. 2008;16:376-384.
38. Sabonghy EP, Wood RM, Ambrose CG, McGarvey WC, Clanton TO. Tendon transfer fixation: comparing a tendon to tendon technique vs. bioabsorbable interference-fit screw fixation. *Foot Ankle Int*. 2003;24:260-262.
39. Sammarco VJ. Complications of lateral ankle ligament reconstruction. *Clin Orthop Rel Res*. 2001;391:123-132.
40. Schenck RC Jr, Coughlin MJ. Lateral ankle instability and revision surgery alternatives in the athlete. *Foot Ankle Clin N Am*. 2009;14:205-214.
41. Stiehl JB, Inman VT. *Inman's Joints of the Ankle*. 2nd ed. Baltimore: Williams & Wilkins; 1991.
42. Sugimoto K, Takakura Y, Kumai T, Iwai M, Tanaka Y. Reconstruction of the lateral ankle ligaments with bone-patellar tendon graft in patients with chronic ankle instability: a preliminary report. *Am J Sports Med*. 2002;30:340-346.
43. Takao M, Oae K, Uchio Y, Ochi M, Yamamoto H. Anatomical reconstruction of the lateral ligaments of the ankle with a gracilis autograft: a new technique using an interference fit anchoring system. *Am J Sports Med*. 2005;33:814-823.
44. Taser F, Shafiq Q, Ebraheim NA. Anatomy of lateral ankle ligaments and their relationship to bony landmarks. *Surg Radiol Anat*. 2006;28:391-397.
45. Waldrop NE, Wijdicks CA, Jansson KS, LaPrade RF, Clanton TO. Anatomic suture anchor versus the Broström technique for anterior talofibular ligament repair: a biomechanical comparison. *Am J Sports Med*. 2012;40:2590-2596.
46. Wang B, Xu XY. Minimally invasive reconstruction of lateral ligaments of the ankle using semitendinosus autograft. *Foot Ankle Int*. 2013;34:711-715.