

# The American Journal of Sports Medicine

<http://ajs.sagepub.com/>

---

## **Anterior Talofibular Ligament Ruptures, Part 1: Biomechanical Comparison of Augmented Broström Repair Techniques With the Intact Anterior Talofibular Ligament**

Nicholas A. Viens, Coen A. Wijdicks, Kevin J. Campbell, Robert F. LaPrade and Thomas O. Clanton  
*Am J Sports Med* 2014 42: 405 originally published online November 25, 2013  
DOI: 10.1177/0363546513510141

The online version of this article can be found at:

<http://ajs.sagepub.com/content/42/2/405>

---

Published by:



<http://www.sagepublications.com>

On behalf of:



American Orthopaedic Society for Sports Medicine

**Additional services and information for *The American Journal of Sports Medicine* can be found at:**

**Email Alerts:** <http://ajs.sagepub.com/cgi/alerts>

**Subscriptions:** <http://ajs.sagepub.com/subscriptions>

**Reprints:** <http://www.sagepub.com/journalsReprints.nav>

**Permissions:** <http://www.sagepub.com/journalsPermissions.nav>

>> [Version of Record](#) - Jan 31, 2014

[OnlineFirst Version of Record](#) - Nov 25, 2013

[What is This?](#)

# Anterior Talofibular Ligament Ruptures, Part 1

## Biomechanical Comparison of Augmented Broström Repair Techniques With the Intact Anterior Talofibular Ligament

Nicholas A. Viens,<sup>\*†</sup> MD, Coen A. Wijdicks,<sup>\*</sup> PhD, Kevin J. Campbell,<sup>\*</sup> BS, Robert F. LaPrade,<sup>\*†</sup> MD, PhD, and Thomas O. Clanton,<sup>\*†‡</sup> MD

*Investigation performed at the Department of BioMedical Engineering, Steadman Philippon Research Institute, Vail, Colorado*

---

**Background:** The concept of utilizing nonabsorbable suture tape fixed directly to bone to augment Broström repairs of the anterior talofibular ligament (ATFL) has been proposed. No biomechanical studies of this technique are available.

**Hypothesis:** We hypothesized that suture tape augmentation alone and Broström repair with suture tape augmentation would have similar biomechanical properties to the intact ATFL at time zero in a cadaveric model.

**Study Design:** Controlled laboratory study.

**Methods:** Eighteen fresh-frozen cadaveric ankles were randomized into 3 groups of 6 specimens each: (1) intact ATFL, (2) suture tape augmentation, and (3) Broström repair with suture tape augmentation. The specimens were loaded to failure to determine the strength and stiffness of each construct.

**Results:** The mean ultimate load to failure of suture tape augmentation ( $315.5 \pm 66.8$  N) was significantly higher than that of the intact ATFL ( $154.0 \pm 63.7$  N) ( $P = .017$ ). The mean ultimate load of the Broström repair with suture tape augmentation ( $250.8 \pm 122.7$  N) was not significantly different from that of the intact ATFL. The mean stiffness of augmentation alone ( $31.4 \pm 9.9$  N/mm) was significantly higher than that of the intact ATFL ( $14.5 \pm 4.4$  N/mm) ( $P = .008$ ). The mean stiffness of the Broström repair with augmentation ( $21.1 \pm 9.1$  N/mm) was not significantly different from that of the intact ATFL.

**Conclusion:** The ATFL with suture tape augmentation is at least as strong and stiff as the native ATFL at time zero in a fresh-frozen cadaveric model.

**Clinical Relevance:** The Broström repair for lateral ankle ligament ruptures is often unsuccessful in circumstances of poor tissue quality. Augmentations, such as with suture tape, have been proposed for these situations. Suture tape used alone or in combination with the Broström repair provided increased strength and stiffness compared with the standard Broström repair, which produced an immediate strength of less than 50% of the intact ATFL. Adding strength to the Broström repair may be valuable in patients with generalized ligamentous laxity, in large patients or elite athletes, or when graft reconstruction is not feasible.

**Keywords:** anterior talofibular ligament (ATFL); Broström repair; lateral ankle ligament rupture; ligament repair augmentation; suture tape

---

<sup>‡</sup>Address correspondence to Thomas O. Clanton, MD, Steadman Philippon Research Institute, 181 West Meadow Drive, Suite 1000, Vail, CO 81657 (e-mail: tclanton@thesteadmanclinic.com).

<sup>\*</sup>Steadman Philippon Research Institute, Vail, Colorado.

<sup>†</sup>The Steadman Clinic, Vail, Colorado.

One or more of the authors has declared the following potential conflict of interest or source of funding: Dr Clanton and Dr LaPrade are consultants for Arthrex Inc. Arthrex provided cadaveric specimens and surgical equipment for this study.

Ankle sprains are one of the most common injuries in sports, accounting for 15% to 20% of all injuries.<sup>10,16</sup> Ankle sprains in the United States' general population are generally seen in emergency departments at a rate of 2.15 per 1000 person-years.<sup>33</sup> Eighty-five percent of sprains involve the lateral ankle, with one third or more of these injuries resulting in chronic disability and approximately 10% to 20% of patients experiencing recurrent sprains.<sup>10,12,18</sup> This ankle instability can subsequently lead to altered ankle kinematics, chondral injuries, and ankle arthritis.<sup>8,15,26,28</sup> Therefore, when patients experience recurrent ankle sprains and instability despite appropriate

nonoperative strategies, surgical treatment is often indicated. Secondary repair of the anterior talofibular ligament (ATFL), the most commonly injured lateral ligamentous structure, was described in 1966 by Broström<sup>7</sup> and has been reported to improve abnormal ankle kinematics with good clinical outcomes and low morbidity.<sup>3,5,31</sup>

Despite the value of the Broström procedure in the treatment of ankle instability, limitations of this technique exist. For instance, at time zero, Waldrop et al<sup>32</sup> demonstrated that both direct suture repair of the ATFL and the use of suture anchors in the fibula or talus had significantly inferior strength compared with the intact ATFL in a cadaveric model. As a result, the need for early protection of all 3 types of Broström repairs and cautious early rehabilitation were emphasized.<sup>32</sup> This corroborated the work of Kirk et al,<sup>17</sup> who also recommended the need for protection of the Broström repair because of ATFL elongation. To manage situations where the tissue is less than adequate, numerous modifications of the original Broström technique have been described,<sup>20</sup> such as reinforcement with the inferior extensor retinaculum described by Gould et al<sup>2,4,14</sup> or the addition of an Evans procedure as described by Girard et al.<sup>13</sup> Nevertheless, clinical concerns over the early strength of these secondary repairs and the need to limit rehabilitation remain. In patients with long-standing lateral ankle instability with attenuated native tissue and in very large patients and/or elite athletes, both of whom are likely to place extra stress on their ankles, the adequacy of these repairs has been questioned.<sup>13,24</sup> To address situations such as these, the concept of using high-strength nonabsorbable suture tape, which prior literature has described for rotator cuff repairs,<sup>6,9,29</sup> to augment Broström repairs of the lateral ankle ligament has been proposed (Mackay, unpublished data, 2012). No biomechanical data are currently available investigating this technique in the ankle.

The purpose of this study was to perform a biomechanical comparison of suture tape augmentation alone and Broström repair with suture tape augmentation to the intact ATFL in a controlled laboratory biomechanical model. We hypothesized that both techniques would have similar biomechanical properties at time zero when compared with an intact isolated ATFL.

## MATERIALS AND METHODS

### Specimens

Eighteen fresh-frozen cadaveric ankles were thawed, dissected, and utilized in part 1 of this 2-part study. Specimens were included if they had no prior ankle ligament tears or surgery, were age  $\leq 65$  years (mean, 53.2 years; range, 31-65 years), and had no history of cancer as the cause of death. Specimens were randomized to 1 of 3 groups to be tested: (1) intact ATFL, (2) suture tape augmentation, and (3) Broström repair with suture tape augmentation. Specimens were kept moist with saline to prevent tissue desiccation throughout testing.

### Surgical Approach

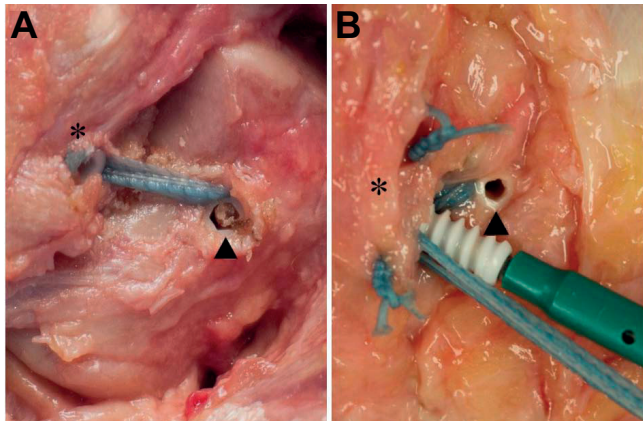
For all specimens, a curvilinear incision was made anterior to the fibula, 3 cm proximal to the ATFL insertion on the talus and extending along the distal anterior fibula. Deeper dissection allowed for identification of the inferior extensor retinaculum. Once identified, the retinaculum was retracted, exposing the underlying ATFL. The capsular interval between the anterior inferior tibiofibular ligament (AITFL) and the ATFL was identified and the ankle joint opened, exposing the lateral trochlea of the talus. A curved hemostat was placed within the joint and passed under the lateral capsule and the ATFL, exiting directly anterior to the peroneal tendon sheath. The capsuloligamentous tissue from the interval between the AITFL insertion and the calcaneofibular ligament (CFL) insertion near the tip of the fibula was then divided, sectioning the ATFL. The specimen was assessed clinically with an anterior drawer test to verify that complete sectioning of the ATFL was performed.

### Isolation of the Intact ATFL and Repair

In all specimens, the intact ATFL or the ATFL repair technique was isolated in a standardized fashion before biomechanical testing. All native soft tissues were stripped completely from the tibia and fibula, with the exception of the ATFL attachment from the distal fibula to the lateral talus. The muscle attachments of the tibia and fibula were removed. The tibia was also removed, leaving the fibula and foot for testing. The foot was left intact with the skin present. An elliptical incision was made across the hindfoot posteriorly at the Achilles insertion. Once the soft tissues were removed, the deltoid ligament, the anterior capsule, and the posterior capsule were incised, leaving the lateral ligaments. The syndesmosis ligaments, the posterior talofibular ligament, and the CFL were then cut, leaving only the intact ATFL or the repaired ATFL isolated in all specimens.

### Suture Tape Augmentation Surgical Technique

In 6 ankle specimens, the capsuloligamentous ends of the ATFL were identified after sectioning but were not sutured together. The sectioned ends of the ATFL were used as guides for tunnel placement. Two 3.4-mm tunnels were created in the fibula and talus at the origin and insertion of the native ATFL, using a calibrated drill guide followed by a 4.75-mm tap (Arthrex Inc, Naples, Florida). Consistency with manufacturer and drill type was emphasized to minimize aperture variability and tunnel dimensions.<sup>11</sup> A 4.75-mm suture anchor (BioComposite SwiveLock, Arthrex Inc) was loaded with 2 mm-wide suture tape composed of braided ultra high molecular weight polyethylene (UHMWPE) and polyester (FiberTape, Arthrex Inc) and seated into the talus. The foot was then held in relaxed plantar flexion (ie, 10°-20°) with 5° of eversion with a bump placed under the tibia, allowing the foot to reduce under the ankle mortise and avoid any anterior translation. A second 4.75-mm anchor loaded with the opposite




**Figure 1.** (A) Suture tape augmentation (right ankle specimen). Ultra high molecular weight polyethylene (UHMWPE) and polyester suture tape in the anterolateral distal fibula (asterisk) and talus (arrowhead) along the lateral articular margin is secured with biocomposite anchors at the origin and insertion points of the anterior talofibular ligament (ATFL). (B) Broström repair with the suture tape augmentation (right ankle specimen). Suture tape is placed superficial to 2 No. 0 UHMWPE and polyester sutures passed through the capsuloligamentous ends and tied in an imbricated position. Suture tape is secured in the talus with an anchor (arrowhead) at the insertion site of the ATFL, while the second anchor loaded with suture tape is placed into the anterolateral distal fibula (asterisk) at the origin of the ATFL.

end of the suture tape was then seated into the fibula under tension (Figure 1A). The anterior drawer test was applied to each specimen to verify stability of the ankle mortise.

### Broström Repair With Suture Tape Augmentation Surgical Technique

In 6 ankle specimens, the capsuloligamentous ends were identified after they were sectioned. Similar to the suture tape augmentation technique, two 3.4-mm drill holes were first placed in the fibula and talus. After creation of the tunnels, attention was paid to the Broström repair of the ATFL. The foot was then held in relaxed plantar flexion with 5° of eversion with a bump placed under the tibia, allowing the foot to reduce under the ankle mortise and avoid any anterior translation. Two No. 0 nonabsorbable braided sutures (FiberWire, Arthrex Inc) were placed through the sectioned capsuloligamentous ends for repair of the ATFL in an imbricated position, similar to the technique described by Broström<sup>7</sup> and others.<sup>32</sup> After securing the Broström repair, a 4.75-mm anchor loaded with suture tape was seated into the previously created talar tunnel superficial to the repair. A second 4.75-mm anchor with suture tape was then seated into the fibula superficial to the repair and the suture tape tensioned (Figure 1B). The anterior drawer test was applied to each specimen to verify stability of the ankle mortise.



**Figure 2.** Left ankle specimen secured in a custom fixture and mounted to the load actuator of a dynamic tensile testing machine before biomechanical testing. The foot is placed in 20° of inversion and 10° of plantar flexion relative to the vertical fibula. Spherical pushpins are placed in the vertical plane at the same height of the insertion sites of the native anterior talofibular ligament footprints in the fibula and talus for detection by the video extensometer.

### Specimen Preparation for Testing

Similar testing methods have been previously published,<sup>32</sup> with modifications for this 2-part study described here in detail. Each specimen was rigidly secured onto a plate with a steel strap over the superior portion of the dorsum of the foot. A 6 mm-diameter drill was used to create an 80 mm-deep pilot hole from posterior to anterior into the calcaneus. To further secure the foot and prevent deflection off the foot plate, a pin was placed into the calcaneus through the back of the custom fixation device, through the pilot hole adjacent to the posterior calcaneus. Two 50-mm screws were placed inferiorly across the subtalar joint to prevent movement during loading. The mounted foot and plate were then placed on a custom alignment fixture with the foot in 20° of inversion and 10° of plantar flexion relative to the vertical fibula. A 6 mm-diameter drill was used to create a medial to lateral tunnel through the fibula, 10 cm proximal from the joint. A 6 mm-diameter pin was placed through the fibular tunnel in a custom

TABLE 1  
Demographics and Mean Ultimate Load to Failure and Stiffness Compared With the Intact ATFL<sup>a</sup>

Group	Demographics		Ultimate Load to Failure				Stiffness			
	Male: Female, n	Age, Mean (Range), y	Mean $\pm$ SD, N	$\Delta$	% $\Delta$	P Value	Mean $\pm$ SD, N/mm	$\Delta$	% $\Delta$	P Value
Intact	4:2	55.6 (45-64)	154.0 $\pm$ 63.7	—	—	—	14.5 $\pm$ 4.4	—	—	—
Augmentation alone	3:3	50.2 (31-65)	315.5 $\pm$ 66.8	161	51	.017	31.4 $\pm$ 9.9	16	52	.008
Broström with augmentation	4:2	54.0 (41-59)	250.8 $\pm$ 122.7	97	39	.175	21.1 $\pm$ 9.1	6	29	.369

<sup>a</sup>ATFL, anterior talofibular ligament.

fixture, which was mounted to the load actuator of a dynamic tensile testing machine (ElectroPuls E10000, Instron Systems, Norwood, Massachusetts). Six plates were compressed into the fibula from 2 levels and 3 directions to surround and ensure the fibula would remain vertical relative to the foot under loading. Finally, the foot plate was secured to the base of the test bed after aligning the fibula in the anatomic neutral orientation relative to the talus.

### Biomechanical Testing

A video extensometer was utilized to accurately measure the displacement of the fibula relative to the talus by tracking the spheres of contrasting 3.0 mm-diameter spherical pushpins, which were placed in the vertical plane at the same height of the insertion sites of the native ATFL footprints in the fibula and talus (Advanced Video Extensometer, Instron Systems) (Figure 2). A tensile load of 15 N was gradually applied over 10 seconds, and the gauge length between the 2 spherical pins was measured by the video extensometer and recorded. This load was then held for 5 seconds to remove potential creep and then loaded to failure by displacing the fibula at a rate of 20 mm/min. The data were recorded by Instron BlueHill 2 software (Instron Systems), and further analysis and calculations were then performed with Microsoft Excel software (Microsoft Inc, Seattle, Washington). Stiffness (N/mm) was calculated during the linear portion of the force-deflection curve, and the load (N) at 3.0 mm of displacement was recorded. The cause and type of each specimen failure were also recorded.

### Statistical Analysis

Statistical analysis was performed with predictive analytics software (SPSS version 20, SPSS Inc, Chicago, Illinois). The study compared data for each group using a 1-way analysis of variance (ANOVA). For ANOVAs that demonstrated a statistically significant difference, a post hoc Tukey honestly significant difference test was conducted to assess the location of the means that were statistically significant between the groups. A significant difference was determined to be present for  $P < .05$ .

### RESULTS

No statistical differences were seen for demographic variables between any of the study groups. Table 1 demonstrates group demographics and the percentage change in both ultimate load to failure and stiffness for the 2 techniques compared with the intact ATFL.

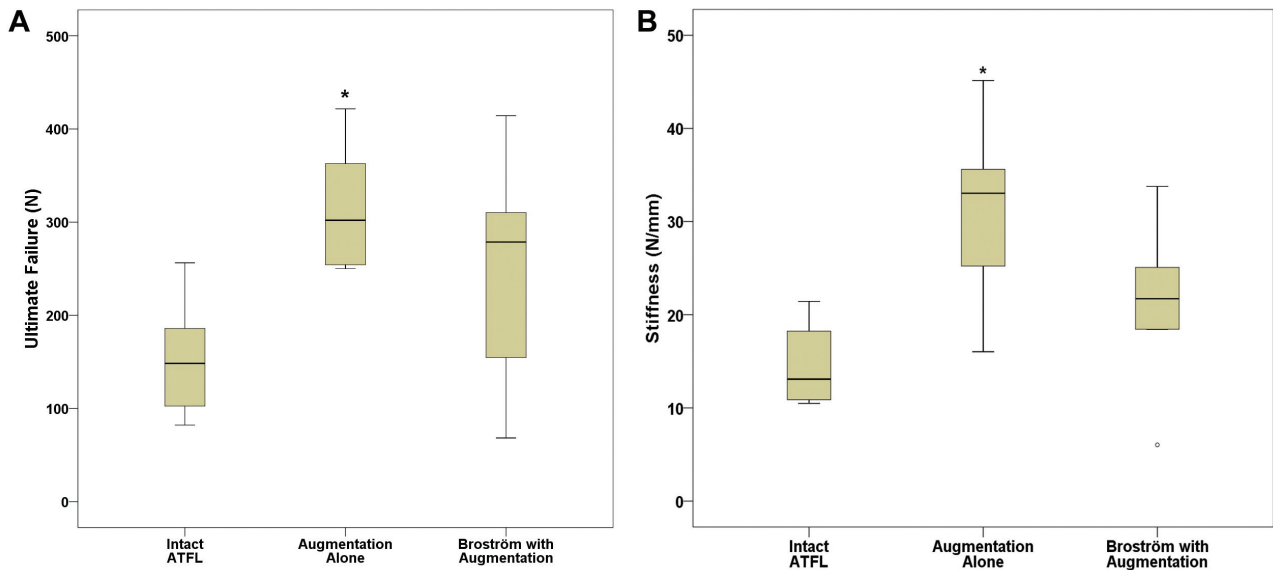
The mean ultimate load to failure of suture tape augmentation (315.5  $\pm$  66.8 N) was significantly higher than that of the intact ATFL (154.0  $\pm$  63.7 N) ( $P = .017$ ). The mean ultimate load to failure of the Broström repair with suture tape augmentation (250.8  $\pm$  122.7 N) was not significantly different than that of the intact ATFL ( $P = .175$ ). The ultimate loads to failure of the 2 techniques were not significantly different from each other ( $P = .436$ ) (Figure 3A).

The mean stiffness of augmentation alone (31.4  $\pm$  9.9 N/mm) was significantly higher than that of the intact ATFL (14.5  $\pm$  4.4 N/mm) ( $P = .008$ ). The mean stiffness of the Broström repair with augmentation (21.1  $\pm$  9.1 N/mm) was not significantly different than that of the intact ATFL ( $P = .369$ ). The stiffness values of the 2 techniques were not significantly different from each other ( $P = .111$ ) (Figure 3B).

The native ATFL failed because of a ligament avulsion at the talus footprint (n = 6/6). Suture tape augmentation failed because of suture pullout of the anchor at the fibula (5/6) and the talus (1/6). The Broström repair with suture tape augmentation failed because of fibular anchor pullout (4/6), talar anchor pullout (1/6), and midsubstance suture elongation (1/6).

### DISCUSSION

The strength and stiffness of the Broström repair with suture tape augmentation were not significantly different from those of the intact ATFL in this cadaveric model. Suture tape augmentation alone demonstrated an approximately 50% higher mean load to failure and stiffness compared with the intact ATFL. The 2 techniques were not significantly different from each other. Given that prior research has reported the ATFL with the standard Broström repair to be at least 50% weaker than the native ATFL at time zero,<sup>32</sup> the results of this study also exhibit that both suture tape augmentation techniques produce



**Figure 3.** Box plots comparing biomechanical data between groups. The horizontal line within the box indicates the median. Each box extends from the 25th to 75th percentile. The vertical bars represent the smallest and largest observed values. The asterisk represents significant differences ( $P < .05$ ). (A) Ultimate load to failure in Newtons (N). (B) Stiffness in Newtons per millimeter (N/mm).

stronger and stiffer results than those of the standard Broström repair.

The present study provides important biomechanical information about both suture tape augmentation alone and suture tape used in conjunction with a Broström repair of the ATFL. Based on these data, however, it remains unclear what clinical role either of these techniques may have in the treatment of patients with lateral ankle instability. Increased strength and increased stiffness compared with the intact ATFL or standard Broström repair do not necessarily translate into a superior treatment option for patients. Additional research and clinical follow-up will be necessary before the widespread use of nonabsorbable suture tape techniques can be recommended for the ankle. In addition to the results of suture tape augmentation, this study also provides further reinforcement of prior research describing biomechanical properties of the intact ATFL. Data from this study reporting the mean ultimate load to failure ( $154.0 \text{ N} \pm 63.7 \text{ N}$ ) of the ATFL compare closely to results reported initially by Attarian et al<sup>1</sup> ( $138.9 \text{ N} \pm 23.5 \text{ N}$ ) and more recently by Waldrop et al<sup>32</sup> ( $160.9 \text{ N} \pm 72.2 \text{ N}$ ).

Caution should be used when making strength and stiffness comparisons between this and prior studies, given the differences in displacement measurement techniques and the variability in custom fixtures. However, the results of the study relative to the intact ATFL provide the ability to interpret between studies of varying test methodologies. Advancements in testing methodology compared with Waldrop et al<sup>32</sup> included maintenance of the fibula in the vertical direction throughout testing, with the surrounding plates in multiple planes designed to prevent migration

of the fibula under loading conditions. Additionally, the calcaneus pin and screws through the subtalar joint assisted in securing the foot on the plate during testing. With the use of the video extensometer, displacement measurements used for stiffness calculations were also more confined to the specific region of interest (ie, change in position of the fibula relative to the talus). Finally, the loads to failure reported by Waldrop et al<sup>32</sup> were more in line with the ATFL itself because the fibula could more easily drift during loading. The force vector on the ATFL or the repair technique in the present study was more representative of the force that occurs during the anticipated mode of failure of a typical inversion-type ankle sprain.

The suture tape augmentation techniques described for the lateral ankle in this study are not necessarily homologous to the “artificial ligaments” and ligament augmentations attempted previously for the anterior cruciate ligament (ACL) of the knee and largely abandoned because of high failure rates.<sup>19,22</sup> Nevertheless, one should not completely ignore that history but instead keep those lessons in mind when evaluating “new” technologies and surgical techniques such as suture tape augmentation for the ATFL. In contrast to the relatively unconstrained articulation of the knee and the intra-articular ACL, the ankle is a highly constrained joint that is more reliant on bony constraints than extra-articular soft tissue structures such as the ATFL.<sup>23,25,27,34</sup> Perhaps these and other differences between the knee and ankle will prove to be critical in future studies evaluating ligament augmentation techniques.

It is important to also mention the issue of appropriate suture tape tensioning when considering the clinical value

of these augmentation techniques. We hypothesize that excess tension on suture tape augmentation could cause stress shielding of the ATFL and result in poor healing of the Broström repair. In contrast, inadequate tension would fail to augment the strength of the overall construct, thereby defeating the theoretical advantage of such an augmentation technique.<sup>21,30,35</sup> Additional research is needed to better understand the clinical significance of this concept in the ankle.

There were limitations to this study. First, the mean age of the specimens was 53.2 years, which is older than the population in which Broström repairs of the ATFL are typically attempted.<sup>10,33</sup> The quality of the soft tissues in the study samples was likely weaker than that seen in younger patients with this clinical problem. Similarly, the bone quality of these older cadaveric specimens was likely to be weaker than in the younger clinical population. In addition, the bone density of the specimen could not be controlled using the methodology of this study. Random assignment of the specimens to each of the 3 experimental groups theoretically decreased the influence of these age-related confounding variables on the study results. Finally, this study demonstrated the biomechanical properties of 2 surgical techniques at time zero only, which eliminates the effects of biological healing over time.

## CONCLUSION

The ATFL with suture tape augmentation is at least as strong as the native ATFL at time zero in a fresh-frozen cadaveric model, with augmentation alone demonstrating 50% higher strength and stiffness compared with the native ligament. Because both suture tape augmentation alone and Broström repair with suture tape augmentation result in comparable or greater strength compared with the intact ATFL, the 2 techniques consequently have increased strength compared with standard Broström repairs described previously in the literature. The clinical role for suture tape augmentation of Broström repairs, specifically the techniques described here, remains to be determined. Additional research is necessary before clinical recommendations about these techniques for ankle ligament ruptures can be made.

## ACKNOWLEDGMENT

The authors acknowledge Kyle S. Jansson for his mechanical expertise in developing the testing fixture for this study.

## REFERENCES

- Attarian DE, McCrackin HJ, Devito DP, McElhaney JH, Garrett WE Jr. A biomechanical study of human lateral ankle ligaments and autogenous reconstructive grafts. *Am J Sports Med.* 1985;13:377-381.
- Aydogan U, Glisson RR, Nunley JA. Extensor retinaculum augmentation reinforces anterior talofibular ligament repair. *Clin Orthop Relat Res.* 2006;442:210-215.
- Baumhauer JF, O'Brien T. Surgical considerations in the treatment of ankle instability. *J Athl Train.* 2002;37:458-462.
- Behrens SB, Drakos M, Lee BJ, et al. Biomechanical analysis of Broström versus Broström-Gould lateral ankle instability repairs. *Foot Ankle Int.* 2013;34:587-592.
- Bell SJ, Mologne TS, Sittler DF, Cox JS. Twenty-six year results after Broström procedure for chronic lateral ankle instability. *Am J Sports Med.* 2006;34:975-978.
- Bisson LJ, Manohar LM. A biomechanical comparison of pullout strength of no. 2 FiberWire suture and 2-mm FiberWire tape in bovine rotator cuff tendons. *Arthroscopy.* 2010;11:1463-1468.
- Broström L. Sprained ankles, VI: surgical treatment of "chronic" ligament ruptures. *Acta Chir Scand.* 1966;132:551-565.
- Caputo AM, Lee JY, Spritzer CE, et al. In vivo kinematics of the tibio-talar joint after lateral ankle instability. *Am J Sports Med.* 2009;37:2241-2248.
- De Carli A, Lanzetti RM, Monaco E, Labianca L, Mossa L, Ferretti A. The failure mode of two reabsorbable fixation systems: Swivelock with Fibertape versus Bio-Corkscrew with Fiberwire in bovine rotator cuff. *J Orthop Sci.* 2012;17:789-795.
- Ferran NA, Maffulli N. Epidemiology of sprains of the lateral ankle ligament complex. *Foot Ankle Clin N Am.* 2006;11:659-662.
- Geeslin AG, Jansson KS, Wijdicks CA, Chapman MA, Fok AS, LaParade RF. Tibial tunnel aperture irregularity after drilling with 5 reamer designs: a qualitative micro-computed tomography analysis. *Am J Sports Med.* 2011;39:825-831.
- Gerber JP, Williams GN, Scoville CR, Arciero RA, Taylor DC. Persistent disability associated with ankle sprains: a prospective examination of an athletic population. *Foot Ankle Int.* 1998;19:653-660.
- Girard P, Anderson RB, Davis WH, Isear JA Jr, Kiebzak GM. Clinical evaluation of the modified Broström-Evans procedure to restore ankle stability. *Foot Ankle Int.* 1999;20:246-252.
- Gould N, Seligson D, Gassman J. Early and late repair of lateral ligament of the ankle. *Foot Ankle.* 1980;1:84-89.
- Harrington KD. Degenerative arthritis of the ankle secondary to long-standing lateral ligament instability. *J Bone Joint Surg Am.* 1979;61:354-361.
- Hootman JM, Dick R, Agel J. Epidemiology of collegiate injuries for 15 sports: summary and recommendations for injury prevention initiatives. *J Athl Train.* 2007;42:311-319.
- Kirk KL, Campbell JT, Guyton GP, Parks BG, Schon LC. ATFL elongation after Broström procedure: a biomechanical investigation. *Foot Ankle Int.* 2008;29:1126-1130.
- Konradsen L, Bech L, Ehrenbjerg M, Nickelsen T. Seven years follow-up after ankle inversion trauma. *Scand J Med Sci Sports.* 2002;12:129-135.
- Legnani C, Ventura A, Terzaghi C, Borgo E, Albisetti W. Anterior cruciate ligament reconstruction with synthetic grafts: a review of the literature. *Int Orthop.* 2010;34:465-471.
- Maffulli N, Ferran NA. Management of acute and chronic ankle instability. *J Am Acad Orthop Surg.* 2008;16:608-615.
- Majima T, Yasuda K, Tsuchida T, et al. Stress shielding of patellar tendon: effect on small-diameter collagen fibrils in a rabbit model. *J Orthop Sci.* 2003;8:836-841.
- Mascarenhas R, MacDonalad PB. Anterior cruciate ligament reconstruction: a look at prosthetics. Past, present and possible future. *McGill J Med.* 2008;11:29-37.
- Rasmussen O. Stability of the ankle joint: analysis of the function and traumatology of the ankle ligaments. *Acta Orthop Scand.* 1985;211 Suppl:1-75.
- Schenck RC Jr, Coughlin MJ. Lateral ankle instability and revision surgery alternatives in the athlete. *Foot Ankle Clin N Am.* 2009;14:205-214.
- Stormont DM, Morrey BF, An KN, Cass JR. Stability of the loaded ankle: relation between articular restraint and primary and secondary static restraints. *Am J Sports Med.* 1985;13:295-300.

26. Sugimoto K, Takakura Y, Okahashi K, Samoto N, Kawate K, Iwai M. Chondral injuries of the ankle with recurrent lateral instability: an arthroscopic study. *J Bone Joint Surg Am.* 2009;91:99-106.
27. Tochigi Y, Rudert MJ, Saltzman CL, Amendola A, Brown TD. Contribution of articular surface geometry to ankle stabilization. *J Bone Joint Surg Am.* 2006;88:2704-2713.
28. Valderrabano V, Hintermann B, Horisberger M, Fung TS. Ligamentous posttraumatic ankle osteoarthritis. *Am J Sports Med.* 2006;34:612-620.
29. van der Meijden OA, Wijdicks CA, Gaskill TR, Jansson KS, Millett PJ. Biomechanical analysis of two tendon posterolateral rotator cuff tear repairs: extended linked repairs and augmented repairs. *Arthroscopy.* 2013;29:37-45.
30. Vieira AC, Guedes RM, Marques AT. Development of ligament tissue biodegradable devices: a review. *J Biomech.* 2009;42:2421-2430.
31. Wainright WB, Spritzer CE, Lee JY, et al. The effect of modified Broström-Gould repair for lateral ankle instability on in vivo tibiotalar kinematics. *Am J Sports Med.* 2012;40:2099-2104.
32. Waldrop NE, Wijdicks CA, Jansson KS, LaPrade RF, Clanton TO. Anatomic suture anchor versus the Broström technique for anterior talofibular ligament repair: a biomechanical comparison. *Am J Sports Med.* 2012;40:2590-2596.
33. Waterman BR, Owens BD, Davey S, Zaccchilli MA, Belmont PJ. The epidemiology of ankle sprains in the United States. *J Bone Joint Surg Am.* 2010;92:2279-2284.
34. Woo SL, Abramowitch SD, Kilger R, Liang R. Biomechanics of knee ligaments: injury, healing and repair. *J Biomech.* 2006;39:1-20.
35. Yasuda K, Hayashi K. Changes in biomechanical properties of tendons and ligaments from joint disuse. *Osteoarthritis Cartilage.* 1999;7:122-129.

---

For reprints and permission queries, please visit SAGE's Web site at <http://www.sagepub.com/journalsPermissions.nav>