



Foot Ankle Clin N Am  
7 (2002) 529-549

FOOT AND  
ANKLE  
CLINICS

## Syndesmosis injuries in athletes

Thomas O. Clanton, MD<sup>a,b,\*</sup>, Paulose Paul, MD<sup>c</sup>

<sup>a</sup>Department of Orthopaedics, University of Texas-Houston Medical School, 6431 Fannin Street, Room 6.156, Houston, TX 77030, USA

<sup>b</sup>Team Physician, Rice University, USA

<sup>c</sup>Department of Orthopaedic Surgery, University of Alberta Medical School, 11048 81<sup>st</sup> Avenue, Edmonton, Alberta, T6G 0S4, Canada

U.S. COPYRIGHT LAW, in accordance with its original copyright notice, protects the work from which this copy was made. Uses may be allowed with permission from the rights holder, or if the copyright on the work has expired, or if the use is "fair use" or within another exemption. The user of this work is responsible for determining lawful users.

A survey of physicians and athletic trainers caring for professional sports teams identified syndesmosis injuries as the most difficult foot and ankle injury to treat [1]. It is well known as a source of persistent disability in high level, as well as recreational, athletes. In a recent prospective examination of athletes with ankle sprains, a sprain of the syndesmosis was the factor that was most predictive of persistent symptoms [2]. Previous studies have also shown that syndesmosis injuries are a greater source of impairment than the typical lateral ankle sprain [3-5].

Injury to the syndesmosis can include a wide spectrum of injury from a minor sprain to frank diastasis of the inferior tibiofibular joint. Diastasis has been defined by Bonnin [6] to be "any loosening of the attachment between the fibula and tibia at the inferior tibiofibular joint and is not confined to a wide separation between the bones". Most cases of diastasis occur with fracture to the fibula; however, it is possible to have a sprain of the syndesmosis without a fracture or diastasis. The entire continuum of syndesmotic injury is considered here.

Syndesmosis injury occurs in 1% to 18% of patients presenting with an ankle sprain. At the United States Military Academy at West Point, there were 15 syndesmosis sprains out of 1344 total ankle sprains [4]. In their series, Cedell [7] and Brostrum [8] reported the incidence rate of syndesmosis injury was approximately 10%. In a more recent study in 1998, Fallat et al [9] reported 31 syndesmosis sprains in their series of 639 acute injuries to the ankle, an incidence rate of about 5%. There seems to be a higher incidence of this injury in high performance athletes. This was suggested in a 1991 study done by Boytim et al [3]. Over a six-year period, they found that 18 of 98 ankle sprains occurring to members of the Minnesota Vikings football team were classified as syndesmosis

\* Corresponding author. Department of Orthopaedics, University of Texas-Houston Medical School, 6-431 Fannin Street, Room 6.156, Houston, TX 77030, USA.

E-mail address: [thomas.o.clanton@uth.tmc.edu](mailto:thomas.o.clanton@uth.tmc.edu) (T. Clanton).

sprains. The higher incidence of syndesmosis sprains among professional athletes was previously shown in a study by Vincelette and co-workers [10]. They demonstrated that 32% of Canadian professional football players had calcification of the distal tibiofibular syndesmosis.

The rate of injury is not only dependent upon the patient population but the definition of the injury and method of diagnosis. The definition of injury can vary between the rather lax criterion that is based on any visit to the athletic trainer, or the criterion may be stricter and require specific loss of playing time. A similar spectrum of inclusion criteria relates to the method of diagnosis from specific point tenderness over the syndesmosis to the more rigid criterion that would require a positive stress radiograph. With such discrepancies in the definition and diagnostic criteria, it is not surprising that there is wide variation in the reported incidence of injury. This article will provide an overview of syndesmosis injuries without concomitant fracture and present treatment guidelines.

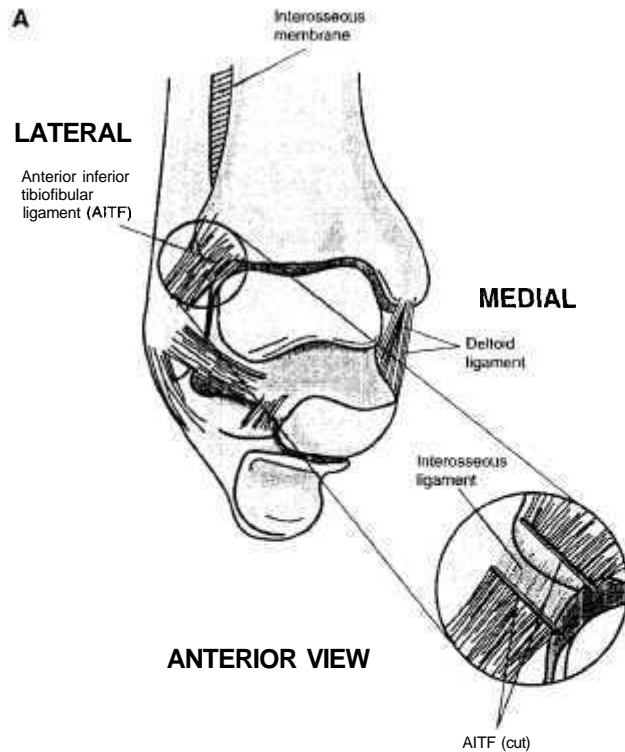


Fig. 1. Ankle anatomy related to the syndesmosis. (A) Anterior view showing anterior inferior tibiofibular ligament, interosseous ligament, and the interosseous membrane. (B) Posterior view showing the two components of the posterior inferior tibiofibular ligament. (C) Lateral view showing the tibia and its fibular notch with the attachment sites of the interosseous ligament and interosseous membrane.

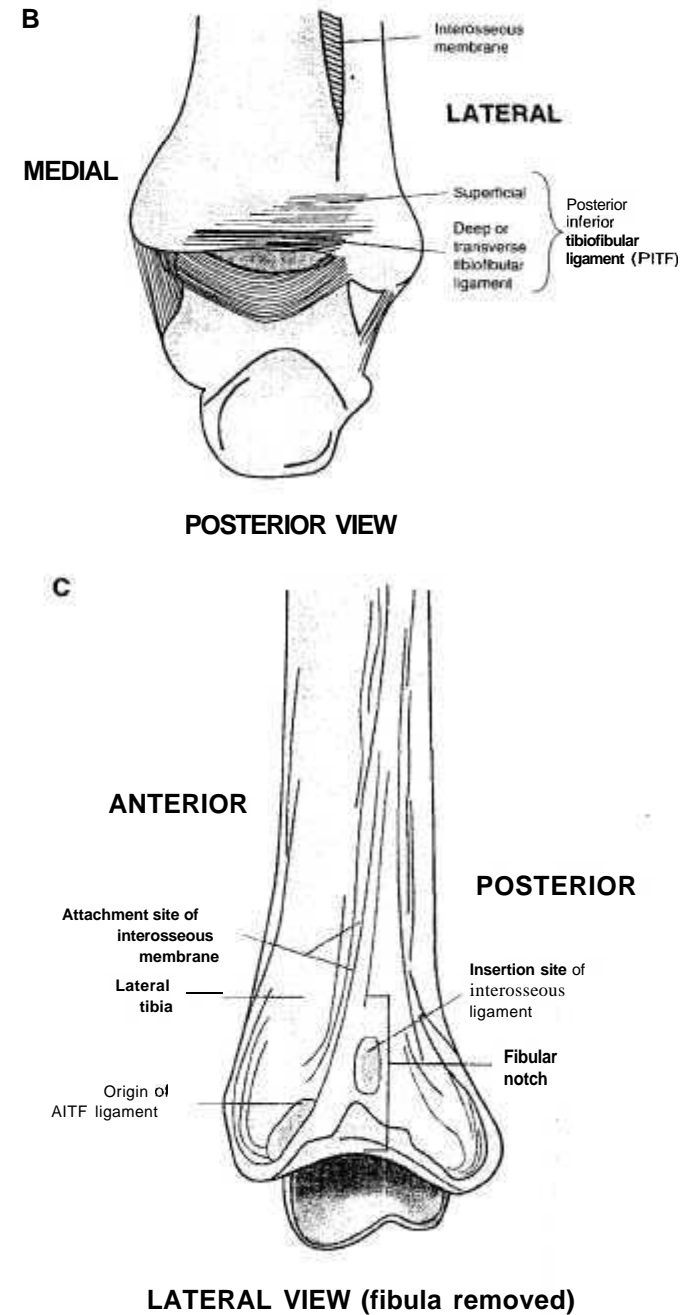


Fig. 1. (continued).

## Anatomy and biomechanics

The interosseous membrane connects the tibia and fibula throughout their lengths. Additionally, there are three main ligaments that add stability to the distal tibiofibular syndesmosis: (1) the anterior inferior tibiofibular (AITF) ligament, (2) the posterior inferior tibiofibular (PITF) ligament, and (3) the interosseous ligament.

The anterior inferior tibiofibular ligament runs obliquely at an approximately 45° angle from the anterolateral tubercle of the tibia (the Tillaux-Chaput tubercle) to the anterodistal fibula (Fig. 1A). The ligament is about 20 mm wide and 20 mm to 30 mm in length [11]. It is often multifascicular, and its most inferior fascicle has been described as a separate structure called the "accessory AITF ligament" or Bassett's ligament [12]. The AITF ligament is the most frequently injured ligament in syndesmosis sprains and in frank diastasis [11].

The posterior inferior tibiofibular ligament has two components (Fig. 1B). The superficial component runs from the posterolateral tubercle on the posterior surface of the tibia to the posterior aspect of the distal part of the fibula. It covers the back of the tibiotalar joint. This superficial component is about 20 mm wide, 30 mm long, and 5 mm thick [11]. The deep portion of the PITF ligament is known as the transverse tibiofibular ligament. It lies anterior to the superficial component of the PITF ligament and forms the most distal aspect of the tibiotalar articulation. It functions similarly to a labrum and deepens the tibiotalar articulation. The fibers of the transverse tibiofibular ligament begin on the medial aspect of the tibia and travel transversely until they insert on the posterior part of the fibula. Its combination of strength and elasticity makes the PITF ligament the last syndesmotomic structure to tear [13,14].

The interosseous ligament connects the tibia and fibula from 0.5 cm to 2 cm above the plafond (see Fig. 1A). It surrounds the synovial recess that extends approximately 1 cm up from the tibiotalar joint. Although it is the shortest structure that connects the distal tibia and fibula, it is considered the primary bond between these two bones at the ankle [15-17]. At the superior margin, the interosseous ligament blends with the interosseous membrane. The membrane adds very little additional strength to the stabilizing effect of the syndesmotomic ligaments.

The bony anatomy of the distal tibia and fibula adds to the inherent stability of the distal tibiofibular complex through containment of the distal portion of the fibula in a region called the fibular notch (Fig. 1C). This is a vertically oriented, concave groove in the lateral surface of the tibia that is bound anteriorly and posteriorly by the tibial tubercles. There can be considerable variation in the size of the tubercles and consequently the depth of the fibular notch; this makes radiographic interpretation of diastasis difficult [6,15]. Hocker and Pachucki [18] showed that the fibular notch is concave only 75% of the time and can also take on a convex appearance.

In the normal relationship between the tibia and fibula, there is motion in all three planes (Table 1). From full plantar flexion to full dorsiflexion there is an increase in the intermalleolar distance of about 1.5 mm. There is also a rotation of

Table 1

Actions of ankle and effects on syndesmosis in different planes of motion [15,18]

Action	Plane of motion	Effect on syndesmosis
Ankle PF to DF	Frontal	Widens IM distance 1.5 mm
Ankle PF to DF	Transverse or horizontal	Tibia rotates 5 to 6 degrees on talus
Loading ankle during stance	Sagittal	Migration of fibula distally 2.4 mm

PF, plantar flexion; DF, dorsiflexion; IM, intermalleolar.

5° to 6° of the tibia on the talus during dorsiflexion and normal walking [15]. In unloaded cadaveric ankles, McCullough and Burge [16] noted up to 25° of rotation in the horizontal plane. Almost half of this motion comes from the inferior tibiofibular joint. Rasmussen et al [19] further defined this motion in the horizontal plane as an average of 7° of internal rotation and 10° of external rotation. Scranton et al [20] showed that the fibula migrates distally an average of 2.4 mm during the stance phase of gait.

The contribution of each of the syndesmotomic ligaments to overall ankle stability has been demonstrated through several studies in which changes in the mobility patterns of the ankle are evaluated after sectioning of the ligaments. Ogilvie-Harris et al [21] demonstrated that the AITF ligament contributes 35% of the stability, the interosseous ligament contributes 22%, the superficial PITF ligament contributes 9%, and the deep PITF ligament contributes 33%. Rupture of two of the three ligaments could, therefore, result in marked instability. Rupture of the AITF can lead to separation between the tibia and fibula of anywhere between 4mm and 12 mm [6,8,22,23]. In a cadaveric study from 1995, Xenos et al [24] showed that sectioning the AITF ligament caused an increase in the separation between the tibia and fibula. This is increased an additional 2.2 mm with sectioning of the interosseous ligament and up to a total of 7.3 mm of separation with sectioning of the PITF ligament. Xenos et al's study also confirmed an increase in rotation of 2.7° with sectioning of the AITF ligament and up to 10.2° when all of the ligaments were sectioned. Although there are some differences in the findings of individual studies looking at relative stability and abnormal motion related to cutting the syndesmotomic ligaments, such differences seem to be attributable to study design and the natural anatomical variations that one would expect [25].

## Mechanism of injury

No study has been able to produce a purely ligamentous injury to the syndesmosis through entirely externally applied stress; however, most clinicians agree that external rotation is the most significant force involved in the mechanism of injury [4,11,13,26]. A syndesmosis sprain may also occur with an abduction force, but this requires rupture of the deltoid ligament or fracture of the medial malleolus as well. With the application of an external rotation force, the AITF ligament is the first to fail, followed by the interosseous ligament and




Fig. 2. Diagrammatic drawing of a typical syndesmosis injury mechanism. A skier hits a pole (or it could be a tree or snow bank) which causes an external rotation of the foot.

then the interosseous membrane. The PITF ligament is usually preserved. The Maissonneuve's fracture of the proximal fibula is the result of a strong and persistent external rotation force. Conversely, O'Donoghue, [27] has suggested that the syndesmosis sprain is the result of a hyperdorsiflexion force.

Several sports activities have been identified as unique because they predispose participants to an external rotation injury mechanism and subsequent increased risk for sprain of the syndesmosis. Slalom skiers have their ankles constrained by a rigid ski boot. If the skier misses a gate by straddling it, the uphill ski is externally rotated rapidly (Fig. 2). A sufficiently violent force can cause a rupture of knee ligaments or a syndesmosis injury with or without concomitant fracture of the fibula [26]. Rodeo bull riders are frequently injured; the bull steps on the lateral aspect of their ankle after throwing the rider [28]. Although athletes are usually unable to describe the exact mechanism of injury, those who are subject to frequent ankle sprains recognize a syndesmosis sprain as a different entity [24].

#### Diagnosis

Patients with acute syndesmosis injuries generally have anterolateral ankle pain directly over the anterior syndesmosis. The pain and swelling are more precisely localized than in patients with the traditional lateral ankle sprain. There

is minimal tenderness over the anterior talofibular or calcaneofibular ligaments. When the mechanism of injury is suspected to have an abduction component, one can expect to have a rupture of the deltoid ligament or a fracture of the medial malleolus with resultant tenderness in one of these locations. The examiner must ensure that the fibula is palpated from distal to proximal, including the proximal tibiofibular joint, to rule out the possibility of a Maissonneuve's fracture. Delayed swelling and ecchymosis are frequent findings.

The "squeeze test" was described in 1990 by Hopkinson et al [4] as a method of detecting "stable" syndesmosis injuries (Fig. 3). In a biomechanical study reported in 1998, Teitz et al [29] confirmed that compression of the fibula and tibia proximal to the midpoint of the calf caused separation at the origin and insertion sites of the AITF ligament. Furthermore, the distance of separation increased as the syndesmotic ligaments were sectioned sequentially. They inferred that pain elicited during this maneuver might be caused by tension in the remaining fibers of the distal tibiofibular complex. Although anterior drawer and

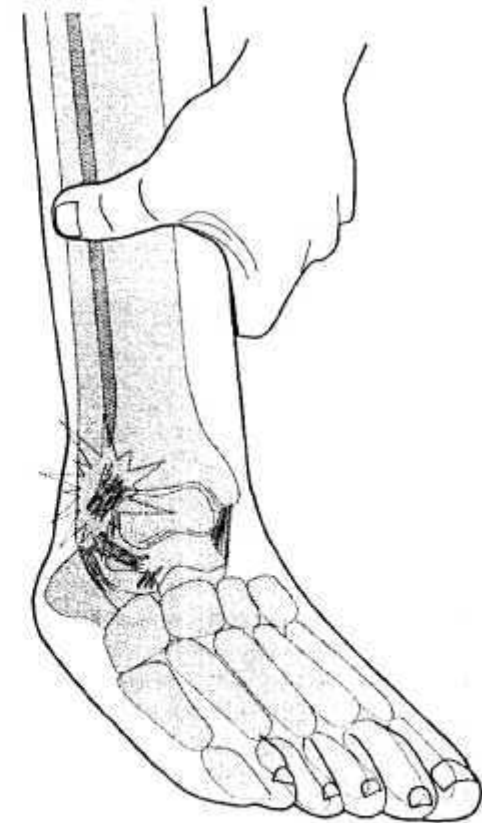


Fig. 3. Method for performing the "squeeze test" for diagnosing injury to the syndesmosis.

talar tilt testing should be performed routinely, one expects these to be negative when the injury is isolated to the syndesmosis. The test that gives the best interrater reliability is the external rotation test (Fig. 4) [30]. This is performed by stabilizing the leg with the knee flexed at 90° and then externally rotating the foot. This should produce pain at the syndesmosis when it is injured.

Routine radiography is the next step in the evaluation of a patient with a suspected syndesmosis injury. It has been reported that these injuries may be associated with a bony avulsion [3,6,26]. Usually, this is a fragment of variable size from the anterior tubercle. In chronic sprains, there may be ossification of the syndesmosis (Fig. 5). Evaluation of the distal tibiofibular relationship is important in achieving a diagnosis. There are three major criteria that define a syndesmosis injury on a radiograph.

First, there is an increase in the medial clear space (Fig. 6). That is, the space between the medial malleolus and the medial border of the talus is usually widened. Normally, this space should be no more than 2 mm to 4 mm [31]. Bonnin [6] has suggested that there is too much variability in the measurement of the medial clear space to allow reliability in the diagnosis of syndesmosis injury.

The second and third parameters is the tibiofibular clear space at the incisura fibularis tibiae and the absolute amount and percentage of overlap of the tibia and fibula at the incisura (see Fig. 6). Based on several anatomic studies, criteria were established in defining the normal tibiofibular relationship at the ankle joint at a 95% confidence level; these are shown in Table 2. Measurement of the tibiofibular clear space was felt to be the most accurate means of determining diastasis [32]. Other studies have attempted to define the normal radiographic

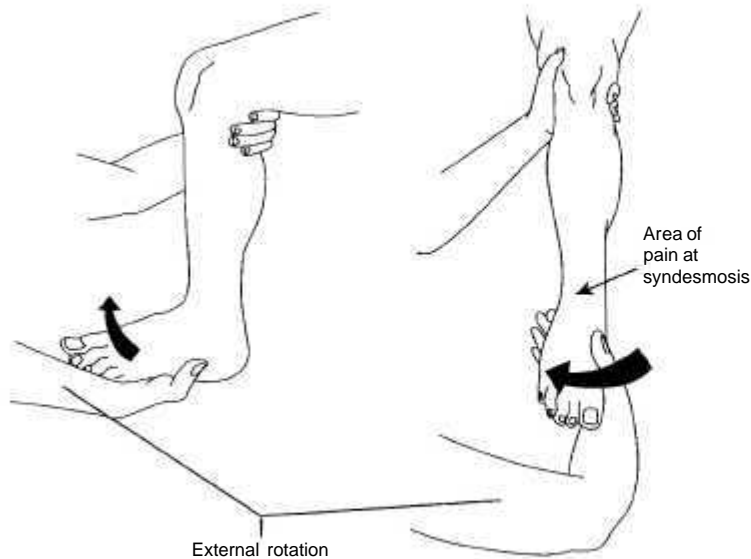


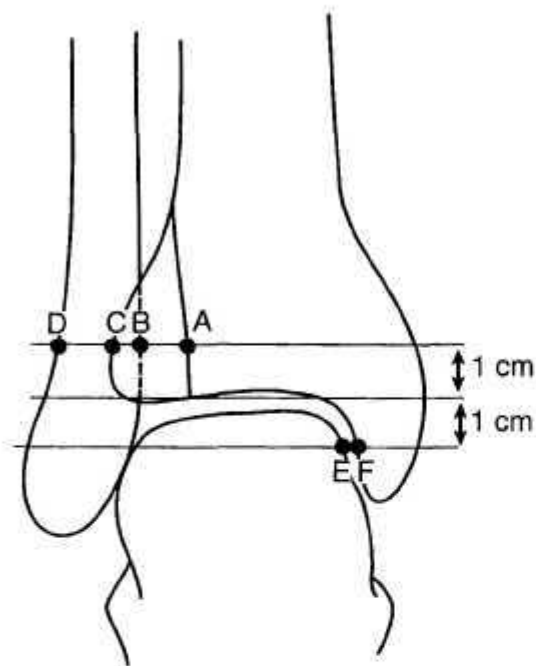
Fig. 4. External rotation test for syndesmosis injury to the syndesmosis.

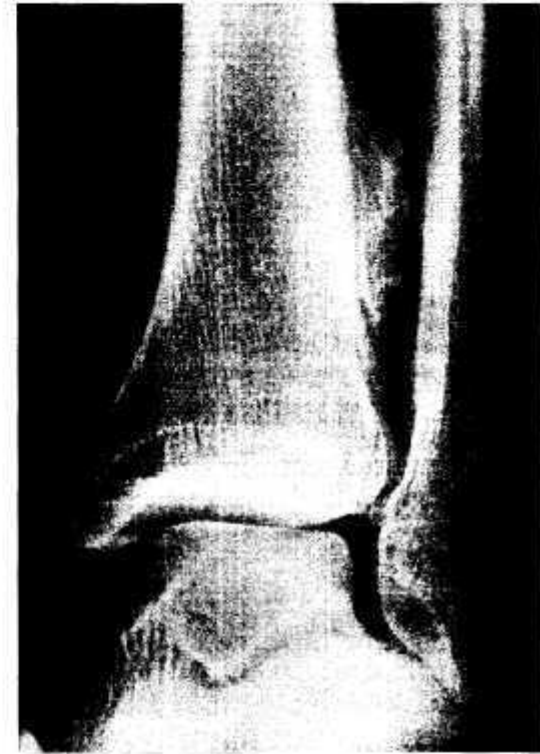

Fig. 5. Radiograph of ankle of a college athlete with mature synostosis following a syndesmosis injury. (Reprinted from Clanton, TO. Athletic injuries to the soft tissues of the foot and ankle. In: Coughlin, MJ, Mann RA, editors. Surgery of the foot and ankle, 7th edition, volume 2. St Louis: Mosby; 1999; with permission.)

anatomy of the distal tibiofibular complex; it seems clear that there is a fair amount of individual variability [33]. A radiograph of the uninjured ankle may aid the clinician in defining the normal or uninjured relationship between the distal tibia and fibula. Criteria for the diagnosis of diastasis are: (1) medial clear space widening, (2) reduced tibiofibular overlap, and (3) increased tibiofibular clear space.

If a clinician suspects a syndesmosis injury despite normal routine radiographs, stress radiographs with application of an external rotation and abduction force can expose an occult diastasis (Fig. 7). Many clinicians advocate the use of stress radiography as standard practice in the diagnosis of syndesmosis injury [3]. Edwards and DeLee [34] used this for classifying diastasis injuries into latent and frank varieties. Frank diastasis is visible on routine radiographs, whereas latent diastasis is apparent only after stress radiographs are obtained. Recently, the role of stress radiographs has come into question. Xenos et al [24] showed that there was only a slight widening of the mortise when an external rotation torque was



- A = Lateral border of posterior tibial malleolus
- B = Medial border of fibula
- C = Lateral border of anterior tibial prominence
- D = Lateral border of fibula
- E = Medial border of talus
- F = Lateral border of medial malleolus
- AB = Tibiofibular clear space
- BC = Tibiofibular overlap
- EF = Medial clear space

Fig. 6. Diagrammatic drawing of radiographic measurements used to diagnose syndesmosis injury. (A), lateral border of posterior tibial malleolus; (D) medial border of fibula; (C) lateral border of anterior tibial prominence; (D) lateral border of fibula; (E) medial border of talus; (F) lateral border of medial malleolus. AD, tibiofibular clear space; BC, tibiofibular overlap; EF, medial clear space.

applied to an ankle despite sectioning all of the ligaments. Ogilvie-Harris and Reed [35] obtained negative stress radiographs in seven patients who all had arthroscopically confirmed syndesmotic injury. Although they are still widely used, stress radiographs are primarily helpful when they clearly demonstrate a latent diastasis that confirms the clinical impression; the rate of false negative studies remains high.

Until the recent advances in diagnostic imaging arthrography was a widely used technique for visualizing the syndesmosis [25]. Arthrography is widely used

Table 2  
Radiographic criteria for diagnosing syndesmosis injury [32,33,46]

X-ray criteria	Normal measurement
Tibiofibular clear space (AP and mortise views)	< 6 mm
Tibiofibular overlap (AP view)	≥ 6 mm
Tibiofibular overlap (Mortise view)	> 1 mm
Ratios	
TF overlap to fibular width	> 24%
TF clear space to fibular width	< 44%

TF, tibiofibular; AP, anterior posterior

in Europe; in the United States, it has been mostly replaced by MRI. Nevertheless, one European study showed that arthrography had a sensitivity of 90% and a specificity of 67% [36].

Bone scans can also demonstrate trauma to the ligaments of the syndesmosis by showing increased uptake in the region of the distal tibiofibular joint. This

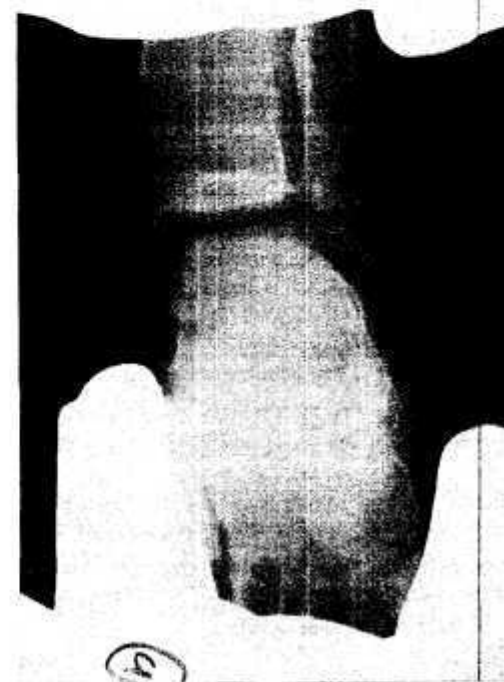


Fig. 7. Stress radiograph demonstrating syndesmosis injury and deltoid ligament tear. (Reprinted from Clanton, TO. Athletic injuries to the soft tissues of the foot and ankle. In: Coughlin, MJ, Mann RA, editors. Surgery of the foot and ankle, 7th edition, volume 2. St Louis: Mosby; 1999; with permission.)

study is particularly useful in the evaluation of a patient with chronic pain after a lateral ankle sprain [25].

More recently, ultrasound has been examined as a tool to aid in the diagnosis of syndesmosis injury. This technique has gained popularity as an in-office method of evaluating patients. A recent study by Milz et al [37] showed that ultrasound has a sensitivity of 67%. Its obvious advantages are the lower cost and the noninvasive nature of the test.

A more critical evaluation of the ankle syndesmosis is afforded by CT and MRI; it is possible to obtain images in axial, frontal, and sagittal planes as well as obtaining three-dimensional reconstructions of the distal tibio-fibular complex. Despite their cost and the need for specialized equipment, these tests are becoming widely used for the evaluation of syndesmotoc injury [25]. Computed tomography is excellent for showing bony detail of the tibiofibular syndesmosis. In a study by Ebraheim et al [38], CT was superior to plain radiographic imaging because it was able to detect 2 mm and 3 mm diastases that were not otherwise apparent.

Magnetic resonance imaging provides an accurate picture of ligamentous anatomy as well as the relationship of the distal tibiofibular joint. It is the most expensive investigation, but gives the most information. It has become the standard for evaluation of the professional athlete suspected to have this injury. Both CT and MRI are useful tests in the acute and chronic settings.

#### Classification

The purpose of any classification scheme is to guide treatment and predict outcome. Many classification schemes have been developed for syndesmosis injuries. The classification scheme outlined in Box 1 is a modification of one developed by Edwards and DeLee [34] that was used to classify diastasis without fracture in the acute setting.

It is useful to differentiate between congenital and acquired conditions because the congenital variety can be associated with other skeletal abnormalities [39,40]. In the acquired category, we differentiate between atraumatic and traumatic conditions; traumatic injuries are divided into acute, subacute, and chronic injuries [25].

Acute syndesmosis injuries are those that are identified within the first 3 weeks postinjury. These can be divided into three sub-categories: (1) sprain without diastasis; (2) latent diastasis, or diastasis that is only apparent after stress radiographs; and (3) frank diastasis. Edwards and DeLee [34] identified four types of frank diastasis. Type I is a frank diastasis with a lateral subluxation of the fibula with no fibula fracture. Type II has a lateral subluxation of the fibula with plastic deformation of the fibula that prevents maintenance of a reduction. Type III involves a posterior subluxation or dislocation of the fibula. This is a very rare form of syndesmosis injury. Type IV is a superior subluxation, or dislocation of the talus into the ankle mortise so that it becomes wedged between the tibia

#### Box 1. Classification of syndesmotoc disorders

- I. Congenital
- II. Acquired: atraumatic (eg, osteochondroma of distal ends of tibia or fibula near syndesmosis)
- III. Acquired: traumatic
  - A. Acute
    1. Sprain without diastasis
    2. Latent sprain
    3. Frank diastasis (per Edwards and DeLee)
      - Type I. Lateral subluxation without fracture
      - Type II. Lateral subluxation with plastic deformation of fibula
      - Type III. Posterior subluxation/dislocation of fibula
      - Type IV. Superior subluxation/dislocation of talus into mortise
  - B. Subacute (3 weeks to 3 months)
    1. Without tibiotalar arthritis
    2. With tibiotalar arthritis
  - C. Chronic (more than 3 months)
    1. Without tibiotalar arthritis
      - a. Without synostosis
      - b. With synostosis
    2. With tibiotalar arthritis

*Data from Edwards GS Jr, DeLee JC. Ankle diastasis without fracture. Foot & Ankle 1984;4(6):305-12.*

and fibula without an associated fibula fracture. It is also quite rare. Injuries that are identified beyond the 3-week stage are classified as subacute; those identified after 3 months are classified as chronic injuries. These categories are subdivided based on the appearance of arthritic changes in the tibiotalar joint. The chronic group is further subdivided based on the presence or absence of a tibiofibular synostosis.

#### Treatment

The treatment of congenital and acquired atraumatic problems of the syndesmosis goes beyond the scope of this article; therefore, we will focus our discussion on the acquired traumatic injury because this is the type that one is most likely to see in the athletic population. There are very few published series that

focus on the treatment of syndesmosis sprains as an isolated injury apart from fibular fractures. The recommendations to follow are a summary of what the senior author (TOC) has gathered from the literature (including that on ankle fractures with a syndesmosis injury) and from personal experience.

Treatment of the acute syndesmosis injury should begin immediately with the RICE formula (rest, ice, compression, elevation). While arranging the appropriate consultations and investigations, the patient should be placed in a short leg splint or walking boot and told to remain nonweight-bearing during the initial postinjury period.

According to the classification system outlined above, a Grade 1 injury is a syndesmosis sprain without diastasis. These injuries are assumed to be stable, and patients are treated symptomatically. A walking boot or stirrup brace is the treatment and patients are instructed that they may be weight-bearing as tolerated. Crutches are provided if weight-bearing is too painful initially. Patients begin rehabilitation of their injury as pain allows. The accurate diagnosis of a syndesmosis injury is important because a lengthier period of disability is the rule compared with a more typical lateral ankle sprain. Several studies have pointed out that patients with syndesmosis injury must wait nearly double the time before they can return to activity [4]. In their series, Taylor et al [41] showed that although 86% of patients reported good to excellent ankle function, stiffness and activity-related pain were frequently persistent problems.

The Grade 2 injury is a syndesmosis sprain that demonstrates latent diastasis. If a closed reduction of the fibula can be documented by CT or MRI, patients do not require surgery. Treatment is immobilization in a nonweight-bearing cast or walking boot for a period of 4 to 6 weeks. Two to 3 weeks postinjury, a repeat weight-bearing plain film should be obtained to confirm continued anatomic reduction of the fibula. After the initial 4 weeks, progressive weight bearing may be started so that the patient is full weight bearing by the end of an additional 4 weeks.

Patients with frank diastasis of the syndesmosis without fracture of the fibula (Grade 3) require operative treatment. Types 3a and 3b injuries, as defined by Edwards and DeLee [34], require surgical stabilization as soon as the soft tissue envelope is healthy. Types 3c and 3d injuries have generally been managed with closed reduction and cast immobilization. It is wise to do this in the operating room under image intensification, because any persistent diastasis will require open reduction and internal fixation.

For repair of the diastasis we recommend the following technique. A standard anterolateral incision is made from 4 cm above to 4 cm below the level of the ankle (Fig. 8). The incision is curved slightly anteriorly at the level of the tibial plafond. Blunt dissection is used through the subcutaneous layers because the superficial peroneal nerve normally crosses the surgical field.

Most commonly there is a tear in the AITF ligament. If there is an avulsed fragment from the anterior tubercle of the fibula or distal tibia, it must be examined to see whether it can be repaired with a small screw or suture anchor

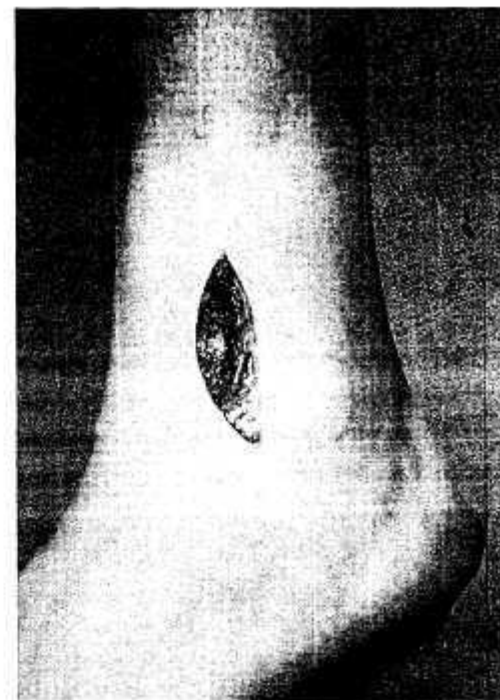


Fig. 8. Photograph showing the anterolateral incision to approach the syndesmosis.

(Fig. 9A,B). When a screw is used, the addition of a soft tissue washer may be helpful unless the fragment is unusually large. If it is difficult to obtain a reduction, then the distal tibiofibular joint must be inspected closely to confirm that there is no debris blocking the reduction. A separate curvilinear incision distal to and paralleling the medial malleolus is used when widening of the medial clear space persists. In this situation, the deltoid ligament is repaired with sutures or suture anchors after clearing debris that is preventing reduction. The sutures should be placed and left untied until the syndesmosis itself is stabilized anatomically.

Plastic deformation of the fibula is another factor that may make reduction of the syndesmosis problematic in the younger patient. The preoperative radiographs must be carefully inspected to ensure that there is no deformation. When deformation is present it requires an osteotomy of the fibula prior to placement of a syndesmosis screw to stabilize the joint. Edwards and DeLee [34] recommended that the fibular osteotomy be performed proximally; a distal osteotomy will be unstable because of damage to the interosseous membrane.

Regardless of the aforementioned factors, once the fibula has been reduced anatomically, the reduction is stabilized with a syndesmosis screw. A transverse



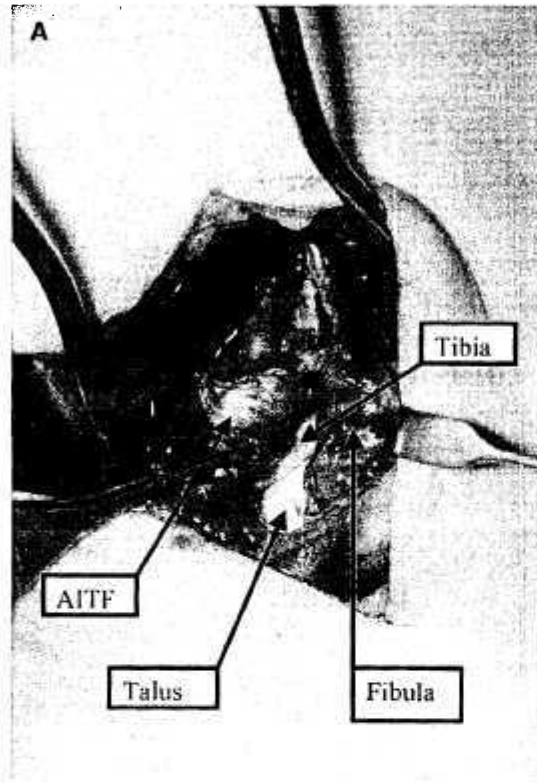


Fig. 9. Syndesmosis injury in 16 year-old football player. (A) Intraoperative photograph of avulsion of AITF ligament from the fibula. (B) Postoperative radiograph demonstrating repair with suture anchor and syndesmosis screw.

drill hole is made beginning at the posterolateral aspect of the fibula at a point 2 cm to 3 cm above the tibial plafond; this keeps the screw from being intra-articular because of the synovial recess between the tibia and fibula. The drill is directed anteriorly into the tibia and four cortices are engaged. A fully threaded cortical screw is the best device to use for stabilization. The optimal size of screw has not been clearly defined although the authors' preference is to use a 4.5 mm screw in most cases. Care should be taken not to overtighten the screw and obtain a lag effect. The benefit of engaging four cortices over three is unproven, but in patients who are very large or have poor bone quality the additional purchase seems advantageous. Also, the use of a longer screw through four cortices can aid in retrieval of a broken screw. It has traditionally been suggested that overtightening the tibiofibular clear space can be avoided by maintaining the ankle in dorsiflexion at the time of final fixation, but this is an unproven concept. After the syndesmosis is stabilized, all soft tissue sutures are tied and the skin and sub-

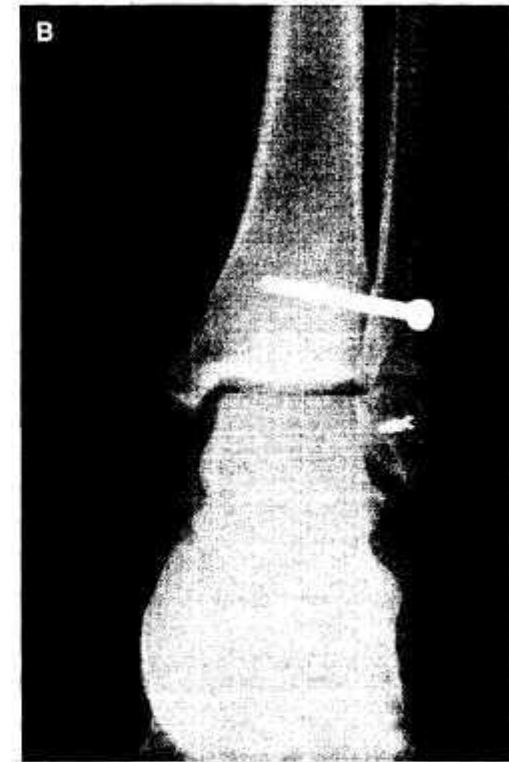

Fig. 9. (continued).

cutaneous tissues are closed. The patient is placed in well-padded posterior and U-shaped splints postoperatively.

Following surgical stabilization of the syndesmosis, patients are kept non-weight bearing for 6 weeks. A below-knee cast or a walking boot is advocated during this period. At the 6-week point, the patient may start partial weight bearing and begin a progressive weight bearing regimen until they are full weight bearing in a walking boot by 10 to 12 weeks. Removal of the syndesmosis screw should occur at about this time. The screw may be left in for a longer period of time at the surgeon's discretion; this is recommended for patients who are heavy (over 220 lbs or 100 kg), or for injuries that do not undergo repair in the acute stage. Immobilization is continued until the screw is removed. Removal of the screw under fluoroscopic guidance allows assessment of stability. Rehabilitation commences with the patient in a stirrup brace. Return to sports or full activities should occur by 6 to 8 months after repair.

The need for screw removal is the major drawback of transsyndesmosis screw fixation. The problem is a disruption of the normal physiologic motion of the

distal tibiofibular joint. In addition to eliminating distal translation of the fibula during gait, transsyndesmotic fixation limits any medial-lateral translation of the fibula during dorsiflexion or plantarflexion of the ankle. This produces a lateral shift in the load distribution on the talus. The use of a bioabsorbable screw may obviate the need for a second operation to remove hardware while still providing stability for the required period of time. This is currently under investigation.

Subacute injuries have no strict treatment guidelines that have been proven effective by clinical studies. Ironically, this is a common presentation because the injury may be missed initially or its severity may be unrecognized. When there is evidence of diastasis, the focus must be to restore the normal anatomy of the distal tibiofibular articulation. Even 1 mm of lateral displacement of the fibula results in a reduction in the available area of tibiotalar contact in weight bearing by 42% [42]. A persistent lack of anatomic reduction can lead to abnormal mechanics that may hasten arthritic changes in the joint. Open reduction and internal fixation with insertion of a syndesmotic screw and repair of the torn ligaments is the appropriate course of treatment whenever this is possible.

At times, the remnants of the AITF ligament are inadequate for repair; in these situations, the use of autogenous or autologous tissue for reconstruction of the AITF ligament is necessary. An autogenous tendon graft can be harvested from the plantaris or the second or third toe extensor. Alternatively, a hamstring tendon graft (semitendinosus or gracilis) may be harvested at the proximal medial tibia. The use of an artificial ligament for reconstruction has been shown to be effective, but we prefer the use of autogenous tissue [43] (Fig. 10).

If repair of the syndesmosis fails or is considered too technically difficult, then a reasonable alternative is the creation of an iatrogenic synostosis between the tibia and fibula. For this procedure, a vertically oriented corticocancellous bone graft is taken from the distal tibia and placed in a slot between the distal tibiofibular joint approximately 1 cm proximal to the plafond. Before insertion of the graft, the adjacent surfaces of the tibia and fibula are roughened with a burr or rasp. The use of two cortical screws that each capture four cortices is advocated in these situations to achieve stability at the syndesmosis. The wounds are closed, and the patient is protected in a nonweight bearing cast for 6 weeks or until there is radiographic evidence of a solid union. Symptoms after this procedure are usually minimal.

For injuries that have been present for longer than 3 months the treatment goals are the same, an anatomic reduction of the distal tibiofibular joint and talocrural joint. Often in these chronic situations there will be articular cartilage changes noted at the time of arthroscopy. Plain radiographs may already show signs of early ossification of the interosseous membrane. It is generally 6 months to 1 year before joint space narrowing, osteophytes, and periarticular erosions begin to appear. Nevertheless, when articular cartilage changes are present, the arthritic outcome of the joint is most likely determined. In this case, considerable discussion with the patient is essential before the selection of the best treatment option. The patient may decide to live with the condition and be treated symptomatically as an alternative to reconstruction or fusion.

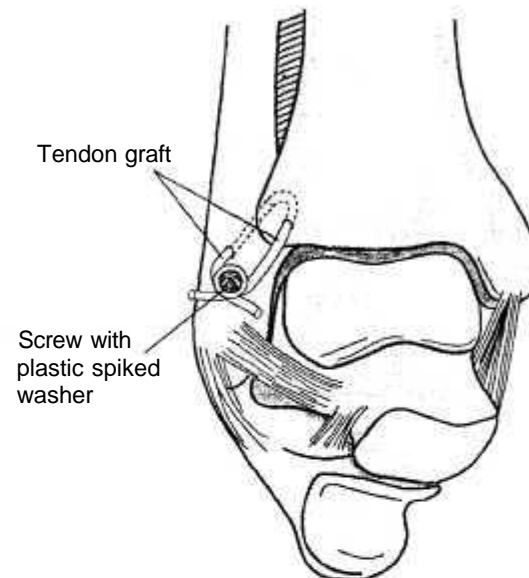


Fig. 10. Illustration of tendon graft method for reconstructing the syndesmosis in a subacute setting.

If there are no arthritic changes, then reconstruction of the syndesmosis is warranted to obtain anatomic alignment. The desired goal is reduction of a persistent diastasis. If a synostosis develops it should not be considered problematic as long as reduction is maintained. The presence of a synostosis is still compatible with high-level athletic performance [44,45].

### Summary

The key to syndesmosis injuries is early recognition of the injury pattern and appropriate treatment. The clinician must be wary of the ankle sprain that is slow to heal. Radiographic criteria should be examined closely when considering the diagnosis; if surgery is warranted, attention to the health of the soft tissue envelope is key. Late repairs or reconstructions never have as favorable an outcome as the properly repaired acute injury. Postoperative rehabilitation should be monitored closely and care should be taken to avoid early return to activity that could result in reinjury or damage to the surgical repair or reconstruction.

### Acknowledgments

Special acknowledgment to Rebecca Wagner and Sherry Franovich for their assistance in the preparation of this article.

## References

- [1] Moseley Jr JB, Chimenti BT. Foot and ankle injuries in the professional athlete. In: Baxter DE, editor. The foot and ankle in sport. New York: Mosby; 1995. p. 321-8.
- [2] Gerber JP, Williams GN, Scoville CR, et al. Persistent disability associated with ankle sprains: a prospective examination of an athletic population. *Foot Ankle Int* 1998;19:653-60.
- [3] Boytım MJ, Fischer DA, Neumann L. Syndesmotic ankle sprains. *Am J Sports Med* 1991;19:294-8.
- [4] Hopkinson WJ, St. Pierre P, Ryan JB, et al. Syndesmosis sprains of the ankle. *Foot Ankle* 1990;10:325-30.
- [5] Taylor DC, Bassett III FH. Syndesmosis ankle sprains. *Physician Sportsmed* 1993;21:39-46.
- [6] Bonnin JG. Injuries to the ankle. Darien (CT): Hafner; 1970. p. 147-85.
- [7] Cedell C. Ankle lesions. *Acta Orthop Scand* 1975;46:425-45.
- [8] Brostrom L. Sprained ankles. III. Clinical observations in recent ligament ruptures. *Acta Chir Scand* 1965;130:560-9.
- [9] Fallal L, Grimm DJ, Saracco JA. Sprained ankle syndrome: prevalence and analysis of 639 acute injuries. *J Foot Ankle Surg* 1998;37:280-5.
- [10] Vincelle P, Laurin CA, Levesque HP. The footballer's ankle and foot. *Can Med Assoc J* 1972;107:872-5.
- [11] Rasmussen O. Stability of the ankle joint: analysis of the function and traumatology of the ankle ligaments. *Acta Orthop Scand* 1985;211:1-75.
- [12] Bassett III FH, Gates III HS, Billys JB, et al. Talar impingement by the anteroinferior tibiofibular ligament: a cause of chronic pain in the ankle after inversion sprain. *J Bone Joint Surg* 1990;72A:55-9.
- [13] Kelikian H, Kelikian AS. Disorders of the ankle. Philadelphia: W.B. Saunders; 1985.
- [14] Sarrafian SK. Anatomy of the foot and ankle: descriptive, topographic, functional. Philadelphia: JB Lippincott; 1983.
- [15] Close JR. Some applications of the functional anatomy of the ankle joint. *J Bone Joint Surg* 1956;38A:761-81.
- [16] McCullough CJ, Burge PD. Rotatory stability of the load-bearing ankle: an experimental study. *J Bone Joint Surg* 1980;62A:460-4.
- [17] Outland T. Sprains and separations of the inferior tibiofibular joint without important fracture. *Am J Surg* 1943;59:320-9.
- [18] Hocker K, Pachucki A. Die incisura fibularis tibiae: die stellung der fibula in der distalen syndesmose am querschnitt. [The fibular incisure of the tibia: the cross-sectional position of the fibula in the distal syndesmosis]. *Unfallchirurg* 1989;92:401-6 [in German].
- [19] Rasmussen O, Tovberg-Jensen I. Mobility of the ankle joint: recording of rotatory movements in the talocrural joint in vitro with and without the lateral collateral ligaments of the ankle. *Acta Orthop Scand* 1982;53:155-60.
- [20] Scranton PE, McMaster JH, Kelly E. Dynamic fibular function. *Clin Orthop* 1976;118:76-81.
- [21] Ogilvie-Harris DJ, Reed SC, Hedman TP. Disruption of the ankle syndesmosis: biomechanical study of the ligamentous restraints. *Arthroscopy* 1994;10:558-60.
- [22] Ashhurst APC, Bromer RS. Classification and mechanism of fractures of the leg bones involving the ankle. *Arch Surg* 1922;4:51-129.
- [23] Cedell C. Supination-outward rotation injuries of the ankle: a clinical and roentgenological study with special reference to the operative treatment. *Acta Orthop Scand* 1967;110:1-148.
- [24] Xenos JS, Hopkinson WJ, Mulligan ME, et al. The tibiofibular syndesmosis: evaluation of the ligamentous structures, methods of fixation, and radiographic assessment. *J Bone Joint Surg* 1995;77A:847-56.
- [25] Clanton TO. Athletic injuries to the soft tissues of the foot and ankle. In: Coughlin MJ, Mann RA, editors. Surgery of the foot and ankle, 7th edition, volume 2. St. Louis: Mosby; 1999. p. 1090-209.
- [26] Fritschy D. An unusual ankle injury in top skiers. *Am J Sports Med* 1989;17:282-6.
- [27] O'Donoghue DH. Treatment of injuries to athletes. 2nd edition. Philadelphia: W.B. Saunders; 1970.
- [28] Slawski DP, West OC. Syndesmotic ankle injuries in rodeo bull riders. *Am J Orthop* 1997;26:794-7.
- [29] Teitz CC, Harrington RM. A biomechanical analysis of the squeeze test for sprains of the syndesmotic ligaments of the ankle. *Foot Ankle Int* 1998;19:489-92.
- [30] Alonso A, Khoury L, Adams R. Clinical tests for ankle syndesmosis injury: reliability and prediction of return to function. *J Orthop Sports Phys Ther* 1998;27:276-84.
- [31] Shereff MJ. Radiographic analysis of the foot and ankle. In: Jahss MH, editor. Disorders of the foot and ankle, 2nd edition. Philadelphia: W.B. Saunders; 1991. p. 91-108.
- [32] Harper MC, Keller TS. A radiographic evaluation of the tibiofibular syndesmosis. *Foot Ankle* 1989;10:156-60.
- [33] Ostrum RF, De Meo P, Subramanian R. A critical analysis of the anterior-posterior radiographic anatomy of the ankle syndesmosis. *Foot Ankle* 1995;16:128-31.
- [34] Edwards Jr GS, DeLee JC. Ankle diastasis without fracture. *Foot Ankle* 1984;4:305-12.
- [35] Ogilvie-Harris DJ, Reed SC. Disruption of the ankle syndesmosis: diagnosis and treatment by arthroscopic surgery. *Arthroscopy* 1994;10:561-8.
- [36] Wrazidlo VW, Karl E, Koch K. Die arthrographische diagnostik der vorderen syndesmosenruptur am oberen sprunggelenk. [Arthrographic diagnosis of rupture of the anterior syndesmosis of the upper ankle joint] *ROFO* 1988;148:492-7 [in German].
- [37] Milz P, Milz S, Steinborn M, et al. Lateral ankle ligaments and tibiofibular syndesmosis. 13 MHz high-frequency sonography and MRI compared in 20 patients. *Acta Orthop Scand* 1998;69:51-5.
- [38] Ebraheim NA, Lu J, Yang H, et al. Radiographic and CT analysis of the tibiofibular diastasis: a cadaver study. *Foot Ankle* 1997;18:693-8.
- [39] Gabarino JL, Clancy M, Hareke T, et al. Congenital diastasis of the inferior tibiofibular joint: a review of the literature and report of two cases. *J Pediatr Orthop* 1985;5:225-8.
- [40] Sedgwick WG, Schoenecker PL. Congenital diastasis of the ankle joint: case report of a patient treated and followed to maturity. *J Bone Joint Surg* 1982;64A:450-3.
- [41] Taylor DC, Englehardt DL, Bassett FH. Syndesmosis sprains of the ankle and the influence of heterotopic ossification. *Am J Sports Med* 1992;20:146-50.
- [42] Ramsay PL, Hamilton W. Changes in the tibiotalar area of contact caused by lateral talar shift. *J Bone Joint Surg* 1976;58A:356-7.
- [43] Becker D. Funktionsgerechte rekonstruktion veralteter syndesmosenprengungen durch implantation von Dacron ligament. [Function related reconstruction of chronic syndesmosis ruptures by implantation of a Dacron ligament] *Beitr Orthop Traumatol* 1990;37:551-61 [in German].
- [44] Ogilvie-Harris DJ, Gilbert MK, Chorney K. Chronic pain following ankle sprains in athletes: the role of arthroscopic surgery. *Arthroscopy* 1997;13:564-74.
- [45] Whiteside LA, Reynolds FC, Ellsasser JC. Tibiofibular synostosis and recurrent ankle sprains in high performance athletes. *Am J Sports Med* 1978;6:204-8.
- [46] Leeds HC, Ehrlich MG. Instability of the distal tibiofibular syndesmosis after bimalleolar and trimalleolar ankle fractures. *J Bone Joint Surg* 1984;66A:490-503.