

An Original Paper

## Sports-Related Spontaneous Fractures of the Humerus

*John V. Marymont, MD;\* Kevin J. Coupe, BS;\* and Thomas O. Clanton, MD\**

### ABSTRACT

**An example of a spontaneous spiral fracture of the humerus in a healthy softball player is presented. This rare injury is discussed, addressing the mechanisms of injury, the treatment, and the types of sports in which this type of fracture has been reported to occur.**

Violent muscular contractions occur in a variety of both contact and noncontact sports and can cause spontaneous fractures. The most common of these is the spiral fracture of the humerus. This occurs at the junction of the upper and middle thirds and is usually associated with a butterfly fragment. The majority of reported cases occur during arm wrestling.<sup>1-6</sup> Throwing a baseball or softball is another common cause.<sup>7-9</sup> The lesion is often seen in pitchers. It is an injury limited to the young, amateur, or poorly conditioned athlete; it has not been reported in professional pitchers.<sup>8</sup> There also are isolated case reports of this

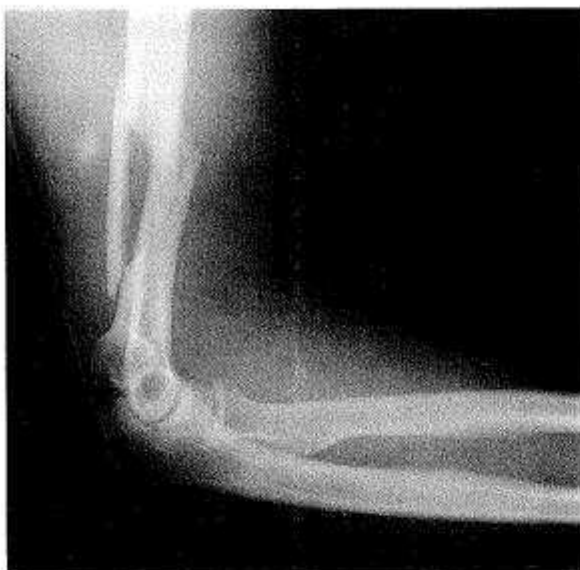injury happening as a result of throwing a hand grenade,<sup>10</sup> the shot (shotputter),<sup>11</sup> or a javelin,<sup>12</sup> or playing cricket<sup>13</sup> or handball.<sup>10</sup>

We present an example of a spontaneous humeral fracture with a butterfly fragment that occurred in a young woman while she was throwing a softball.

### CASE REPORT

A 28-year-old, muscular woman "felt something pop" and developed severe pain in the right elbow immediately after throwing a softball. She was unable to move the elbow. When seen shortly thereafter, she was holding the arm inwardly rotated with the elbow flexed to 90 degrees. There was swelling and tenderness in the distal arm, with obvious posterior deformity. There was no vascular or neural compromise to the extremity, and movement of the wrist and fingers was normal. She had no prior history of upper extremity pain. Her past medical history was unremarkable. A radiograph (Figure 1) showed a spiral butterfly fracture of the distal humeral shaft with a butterfly fragment in an otherwise normal bone. Treatment consisted of closed reduction, with the arm immobilized in a coapta-

\*Dr. Marymont is a Resident, Mr. Coupe is a Medical Student, and Dr. Clanton is a Clinical Assistant Professor, in the Division of Orthopaedic Surgery, The University of Texas Medical School at Houston, Houston, Texas.



**Figure 1.** Radiograph of the distal right humerus and elbow. There is a spiral fracture of the distal humerus with a large butterfly fragment.

tion splint. Subsequently, she was placed in a humeral fracture brace. She healed uneventfully (Figure 2).

## DISCUSSION

Upper extremity injuries account for approximately 20% of all athletic injuries. Currently, softball is one of the largest team participation sports in the United States, with more than 30 million adults and youngsters participating annually.<sup>14</sup> Schesser et al have shown the rate of softball injuries requiring emergency room visits to be 2.26 injuries per 1,000 players per day; fractures represented 42% of the upper extremity injuries in this group of athletes.<sup>15</sup>

Spontaneous fracture of the humerus is uncommon as a sports injury. It was documented at least as early as 1916.<sup>16</sup> Most such fractures occur in the act of overhand throwing a softball or baseball, or during arm wrestling. Usually, there is a spiral, oblique fracture frequently comminuted with a butterfly component. The mechanism for this type of injury and fracture pattern is

not known, but are probably related to the basis of the biomechanics of throwing.

Several authors have examined the biomechanics of the act of throwing.<sup>17,20</sup> There are three phases of throwing: cocking, acceleration, and follow-through. The cocking phase is the interval between the initiation of wind-up and the point at which the shoulder is in maximum external rotation. The acceleration phase then begins, and it ends with ball release. The follow-through starts with ball release and terminates with the cessation of the throwing motion. During these three phases, the upper extremity must endure tremendous forces over a short time.<sup>18</sup>

The acceleration phase lasts approximately 50 milliseconds (ms), with peak angular velocities of 6,180 degrees per second of shoulder internal rotation and 4,595 degrees per second per second of elbow extension. The upper extremity then decelerates in the follow-through, phase. Decelerations values of -500,000 degrees per second per second are recorded in the shoulder and elbow in a 350-ms span.<sup>18</sup> Jobe et al<sup>19</sup> have shown the largest amount of muscle activity to be associated with the deceleration, or follow-through phase. The subscapularis internally rotates the shoulder while the supraspinatus, infraspinatus, teres minor, and deltoid decelerate the arm. The elbow decelerates from extreme extension to abrupt flexion by the biceps.<sup>20</sup> The difference in forces generated by the musculature in the upper extremity between acceleration and deceleration creates a torsion on the shaft of the humerus. It is this torsion that likely exceeds the tensile strength of bone and thus causes the spiral fracture.

Stress fracture of the humerus has been reported.<sup>21</sup> This occurs as a result of repetitive activities such as pitching and is associated with a prodrome of arm pain at rest and with activity.<sup>22</sup> Repeatedly loaded adult cortical bone loses tensile strength more rapidly than it loses compressive

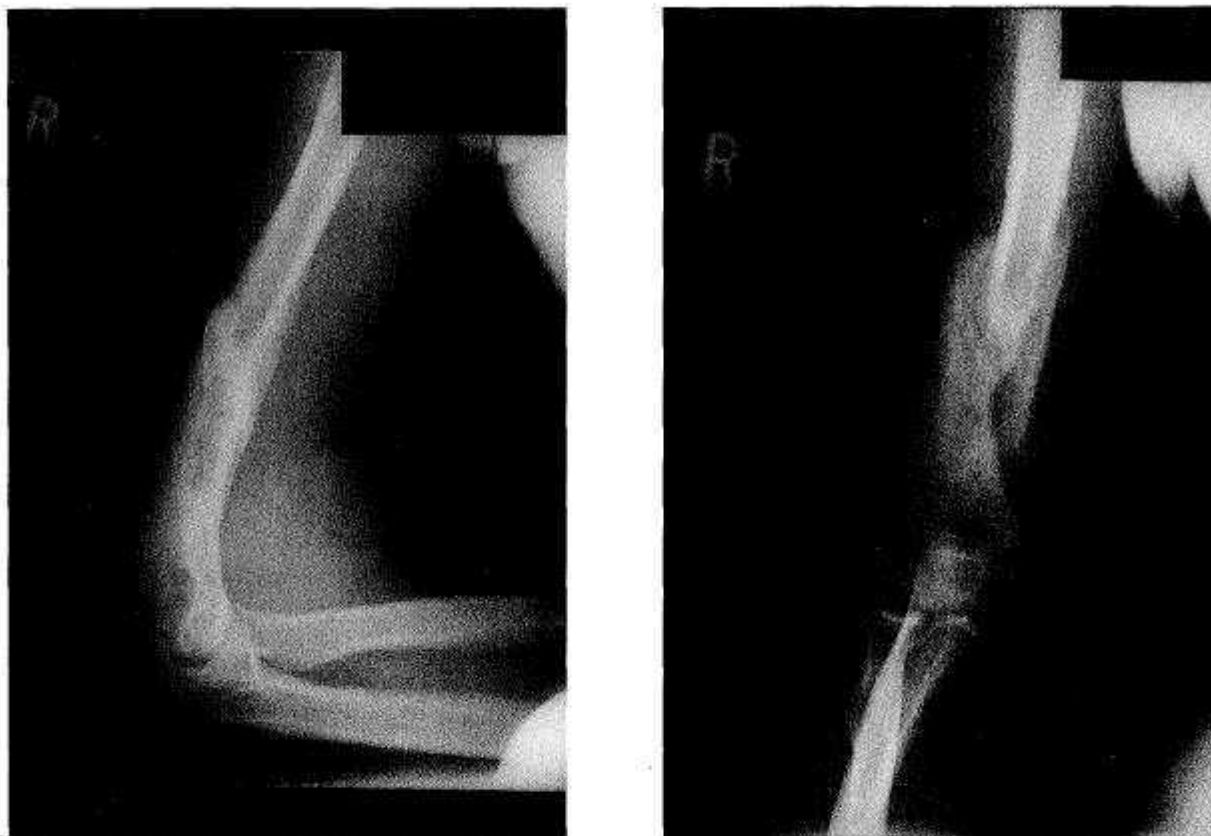


Figure 2. Radiographs of the humerus following conservative treatment. The fracture is healed with acceptable alignment.

strength.<sup>21,23</sup> With repetitive loading or sudden additional forces, a stress fracture can become an overt fracture.

The mechanism underlying fractures sustained during arm wrestling depends, at least in part, on the position of the arm at the time the fracture occurs.<sup>6</sup> At the beginning of the match, when the arm is vertical, the forces are a combination of humeral torsion and humeral bending. As an individual begins to lose the contest, the importance of humeral torsion diminishes, and humeral axial compression and bending become the major factors.

The diagnosis of sports-related spontaneous humeral fracture is usually evident from an accurate history and physical examination. Lesions such as fibrous dysplasia, bone cysts, tumors, and infections, can weaken the bone, making it susceptible to

fracture. These are usually evident on plain radiographs. Rarely, sports-related spontaneous humeral fractures are secondary to underlying bone disease. In our institution, a skeletally immature boy presented after throwing a baseball. In addition to the humeral fracture, the radiograph revealed scalloping of the entire humeral intramedullary cortex. Fine needle aspiration revealed *Staphylococcus aureus*. The diagnosis was spontaneous humeral fracture during the act of throwing, secondary to humeral osteomyelitis.

The treatment of sports-related spontaneous humeral fracture does not differ from that of other forms of nonpathologic midshaft humeral fractures. It can be treated conservatively by coaptation splinting followed by humeral fracture bracing.<sup>24,25</sup> Cosmetic appearance and

function of the extremity will be maintained if alignment remains within 20 degrees of anterior angulation and 30 degrees of varus angulation.<sup>26</sup>

When an apparently healthy individual presents with a spontaneous humeral fracture sustained during an athletic event, the primary physician must consider an etiology based on biomechanical principles. The diagnosis is confirmed by a precise history, the findings of the physical examination, and plain radiographs. Conservative treatment can provide excellent results.

## REFERENCES

1. Brismar B, Spangen L. Fractures of the humerus from arm wrestling. *Acta Orthop Scand* 1975;46:707-708.
2. Heilbronner DM, Manoli A, Morawa LG. Fractures of the humerus in arm wrestlers. *Clin Orthop* 1980;149:169-171.
3. Moon MS, et al. Arm wrestlers injury. Report of seven cases. *Clin Orthop* 1980;147:219-221.
4. Peace PK. Fractures of the humerus from arm wrestling. *Injury* 1977-1978;9:162-163.
5. Rooker GD. An unusual case of a spiral fracture of the humerus. *Injury* 1977-1978;9:62-63.
6. Whitaker JH. Arm wrestling fracture—a humerus twist. *Am J Sports Med* 1977;5:66-77.
7. Herzmark MH, Klune FR. Ball-throwing fracture of the humerus. *Med Ann DC* 1952;21:196-199.
8. Tullos HS, et al. Unusual lesions of the pitching arm. *Clin Orthop* 1972;88:169-182.
9. Tullos HS, King JW. Lesions of the pitching arm in adolescents. *JAMA* 1972;220:264-271.
10. Gregersen HN. Fractures of the humerus from muscular violence. *Acta Orthop Scand* 1971;42:506-512.
11. Santavirta S, Kiviluoto O. Transverse fracture of the humerus in a shotputter: A case report. *Am J Sports Med* 1977;5:122-123.
12. Peltokallio P, Peltokallio V, Vaalasti T. Fractures of the humerus from muscular violence in sports. *J Sports Med Phys Fitness* 1986;8:21-25.
13. McLearie M. Letter to the editor. *Injury* 1981-1982;11:258.
14. Wheeler BR. Slow pitch softball injuries. *Am J Sports Med* 1984;12:237-240.
15. Shesser R, Smith M, Ellis P, et al. Recreational softball injuries. *Am J Emerg Med* 1985;3:199-202.
16. Scudder CL. *Treatment of Fractures*. Philadelphia: WB Saunders, 1916.
17. Gowan ID, Jobe FW, Tibone JE, et al. A comparative electromyographic analysis of the shoulder during pitching. *Am J Sports Med* 1987;15:586-590.
18. Pappas AM, Zawacki RM, Sullivan TJ. Biomechanics of baseball pitching. *Am J Sports Med* 1985;13:216-222.
19. Jobe FW, Tibone JE, Perry J, Moynes D. An EMG analysis of the shoulder in throwing and pitching. A preliminary report. *Am J Sports Med* 1983;11:3-5.
20. Jobe FW, Moynes DR, Tibone JE, Perry J. An EMG analysis of the shoulder in pitching. A second report. *Am J Sports Med* 1984;12:218-220.
21. Allen ME. Stress fracture of the humerus. A case study. *Am J Sports Med* 1974;12:244-245.
22. Devas M. *Stress Fractures*. New York: Churchill-Livingstone; 1975:174-178.
23. Frankel VH, Nordin M. *Basic Biomechanics of the Skeletal System*. Philadelphia: Lea & Febiger; 1980:21-60.
24. Sarmiento A, Kinman PB, Galvin GE, et al. Functional bracing of fractures of the shaft of the humerus. *J Bone Jt Surg* 1977;59A:596-601.
25. Rockwood CA, Green DP. *Fractures in Adults*. Philadelphia: JB Lippincott; 1975:1:653-674.
26. Klemmerman L. Fractures of the shaft of the humerus. *J Bone Jt Surg* 1966;48B:105-111.